Upper Limb

Dr. Matthew Szarko

mszarko@sgul.ac.uk



Range of Motion

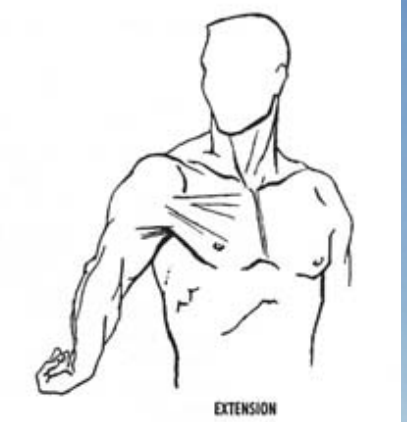

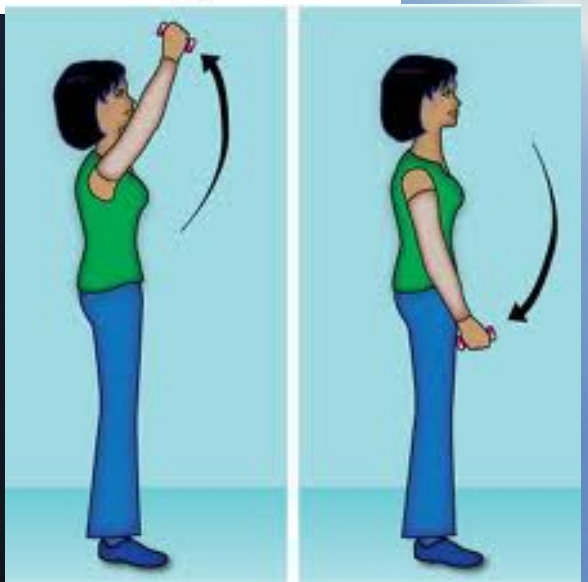

- Flexion
- Extension

Range of Motion

- Abduction
- Internal and External Rotation

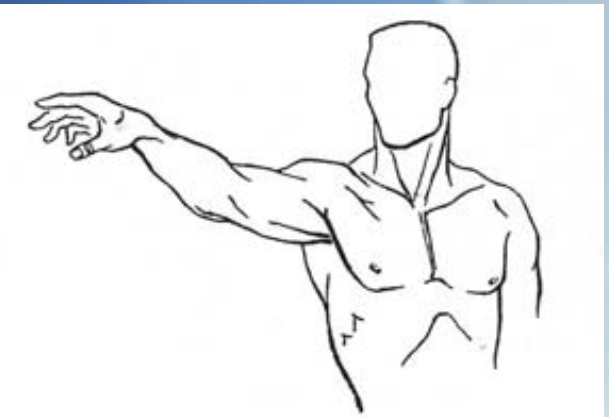

ABDUCTION, PLANE OF SCAPULA

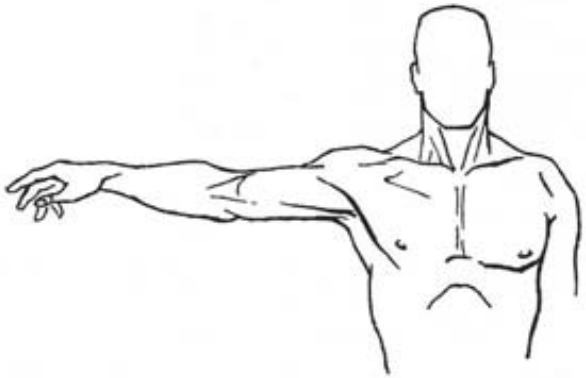

ABDUCTION, CORONAL PLANE

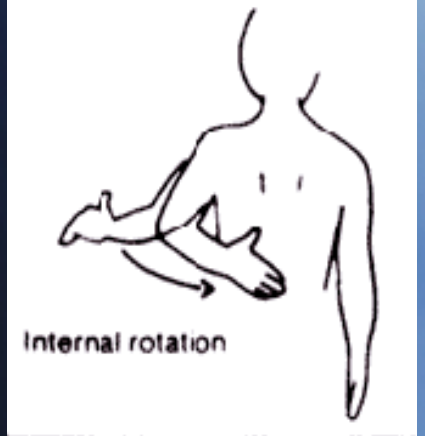

Clavicle

- Protects underlying brachial plexus and vascular structures.
- Elevates along with upper limb elevation.

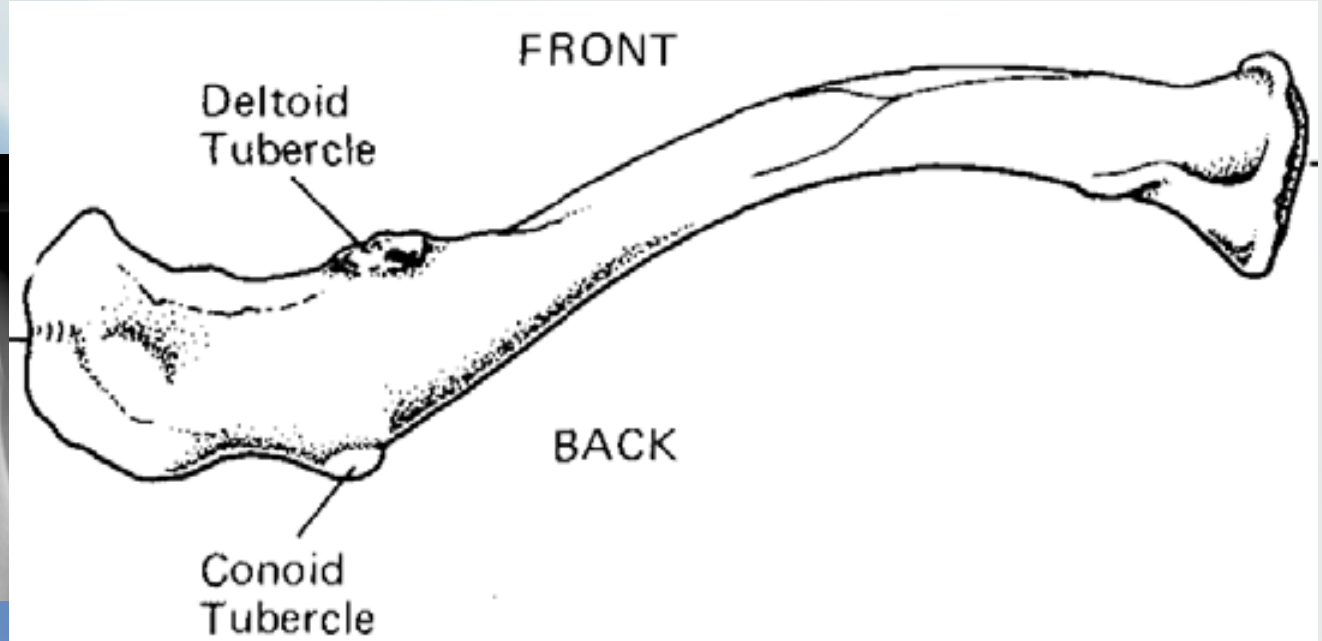

Sternoclavicular Joint

- Only bony connection of upper limb to thorax.
- ~4° of clavicular elevation occurs for every 10° arm elevation at this joint.

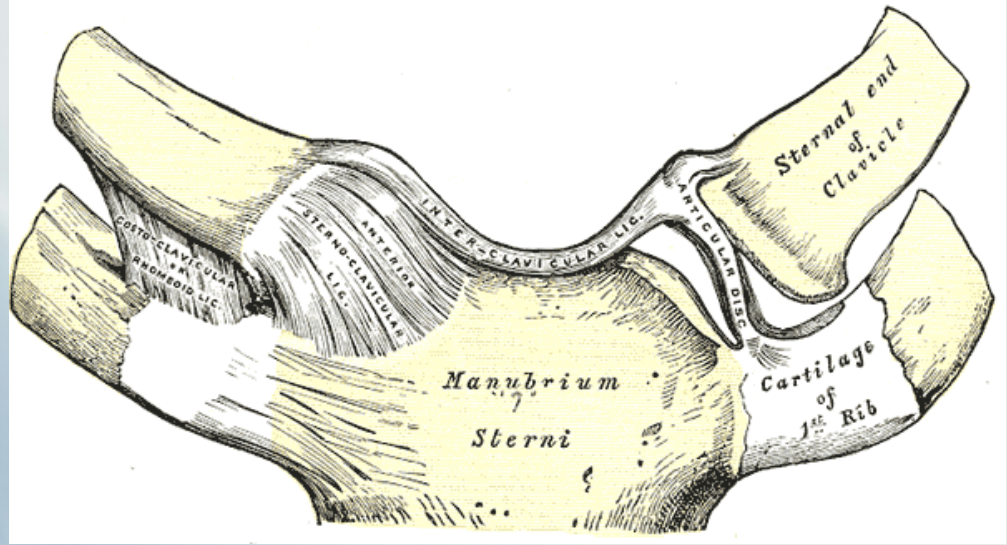

Scapula

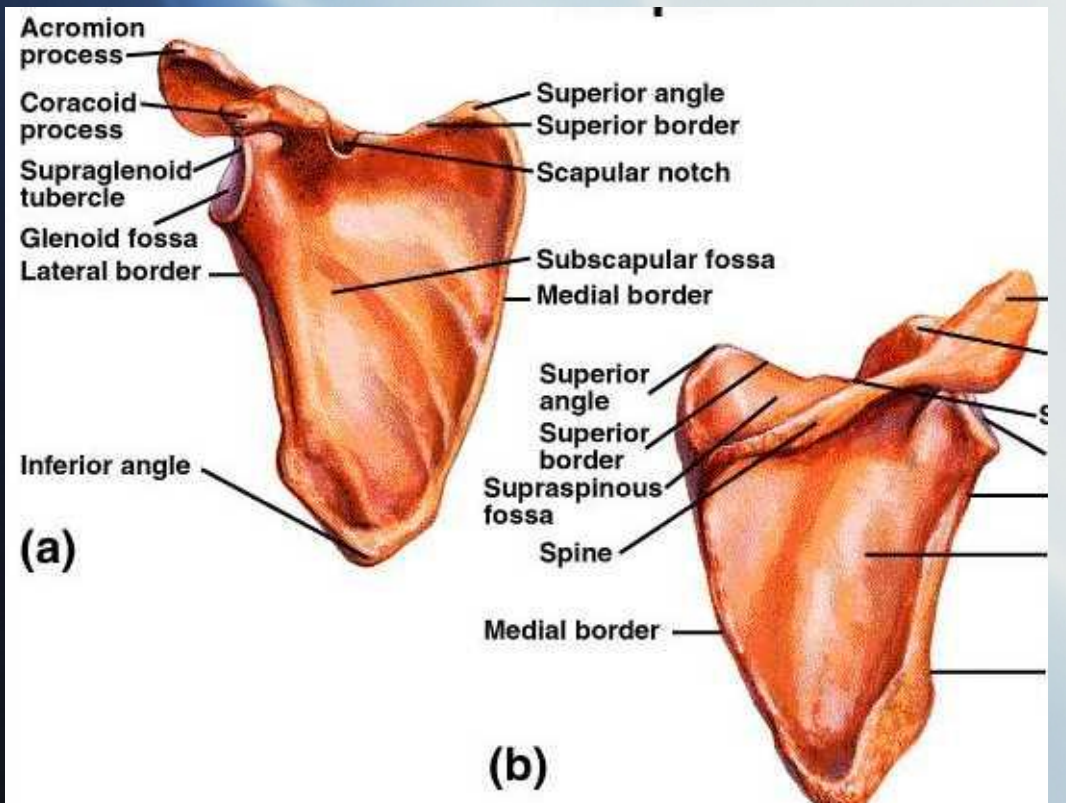

- Spine
- Acromion
- Coracoid process
- Supraglenoid tubercle
  - Long head of biceps brachii
- Infraglenoid tubercle
  - Triceps brachii origin
- Supraspinous fossa
- Infraspinous fossa
- Subscapular fossa

Scapulothoracic Articulation

- Protraction
- Retraction
- Elevation-Depression
- Rotation- during arm flexion.

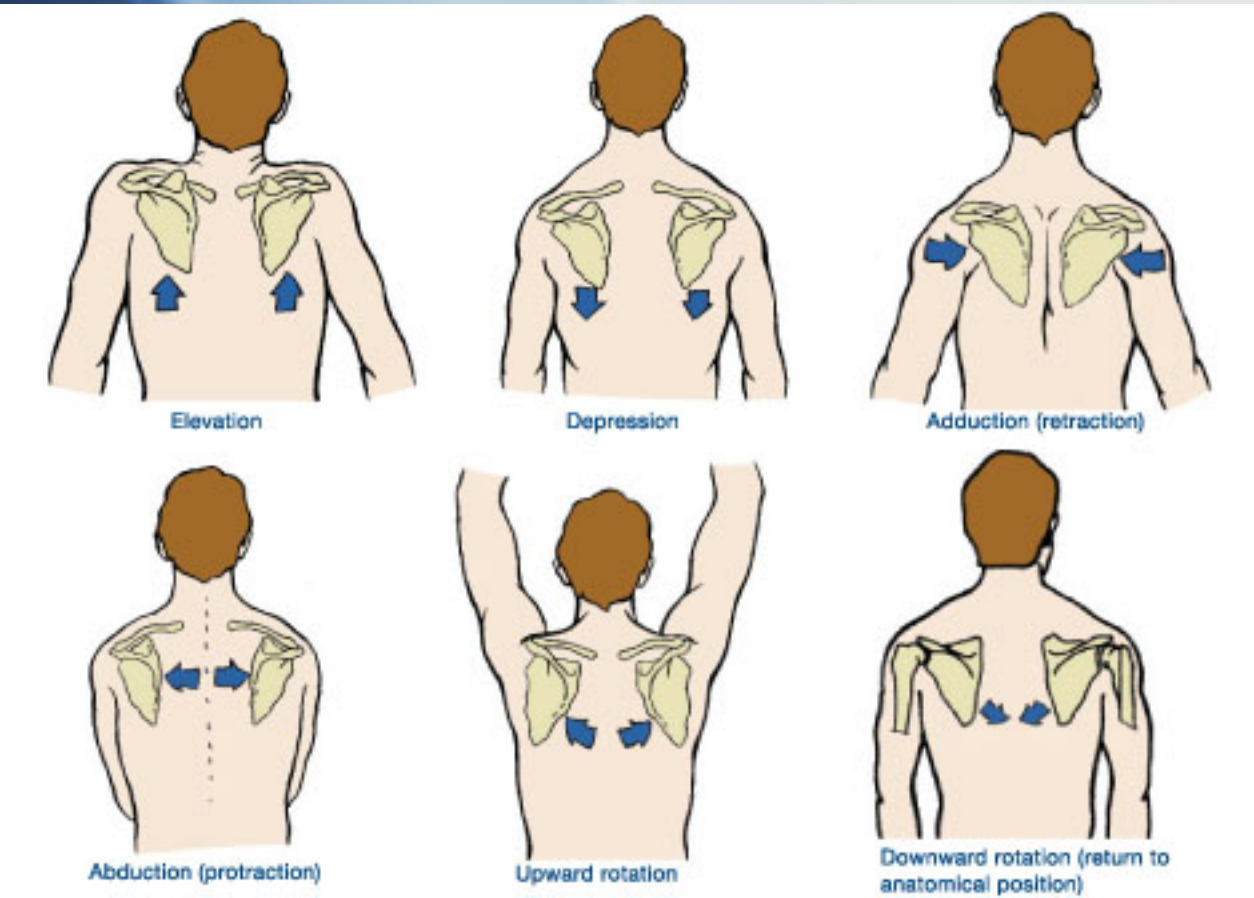

Proximal Humerus

- Head
  - Anatomical neck
  - Surgical neck

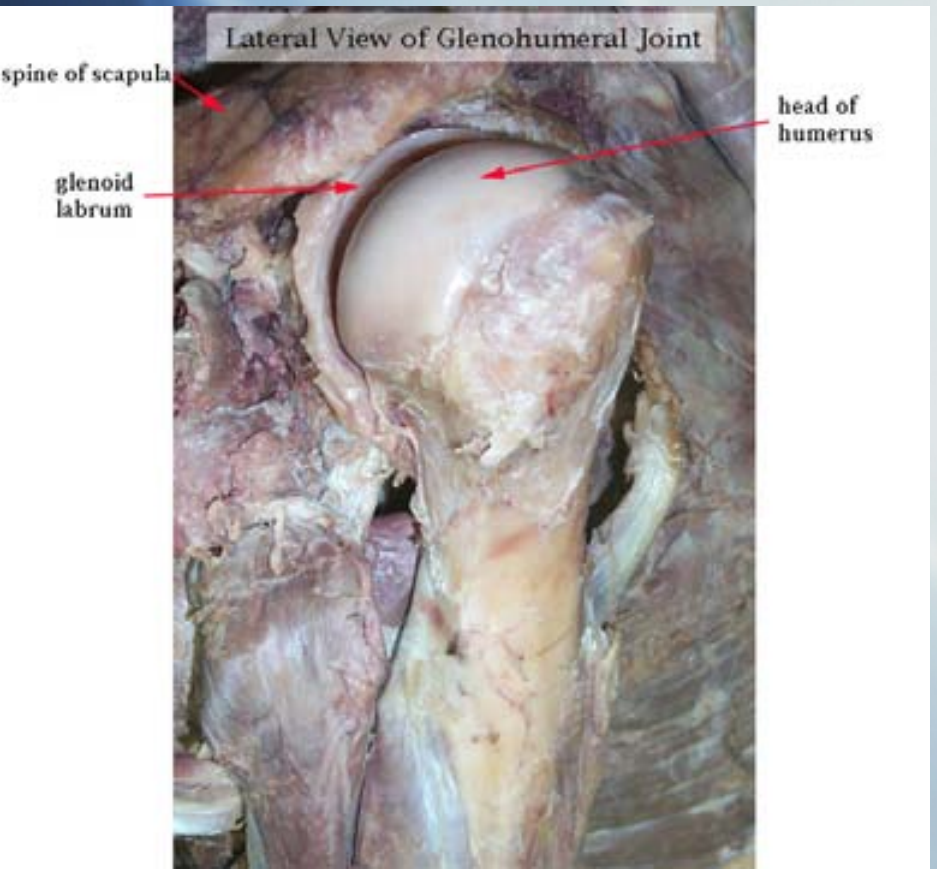

Proximal Humerus

- Greater tubercle
- Lesser tubercle

* Serve as attachments sites for rotator cuff musculature.

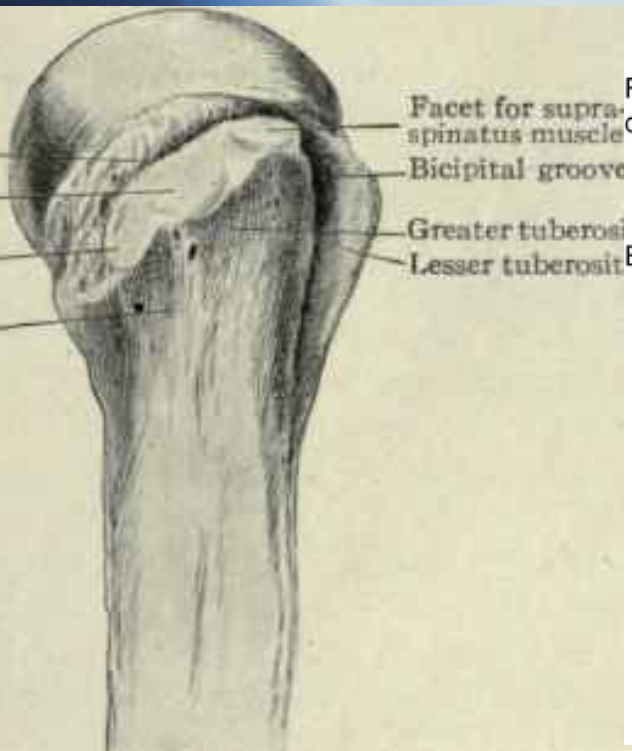

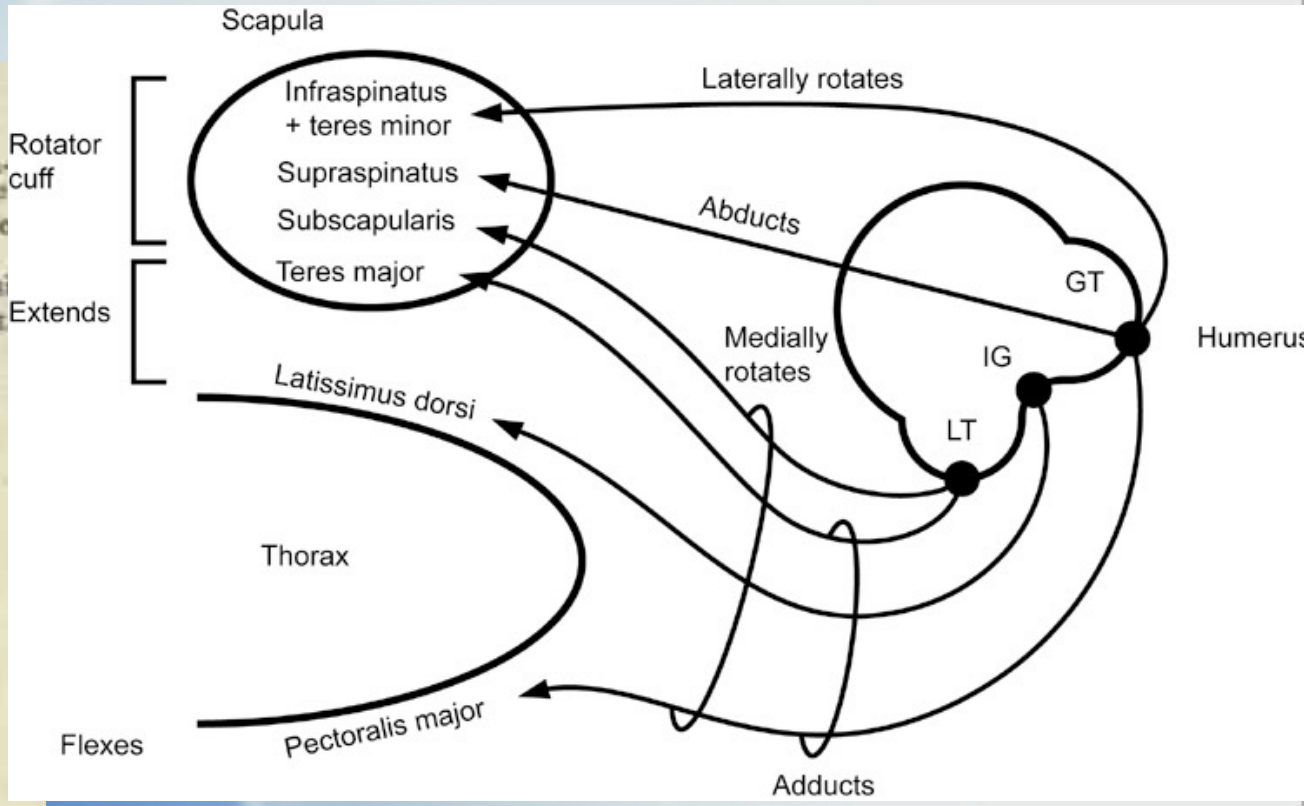

Glenohumeral Joint

- Glenoid labrum
  - Is fibrocartilaginous and provides 50% of overall glenohumeral depth.
  - Superior portion of labrum congruent with tendon to long head of biceps brachii.

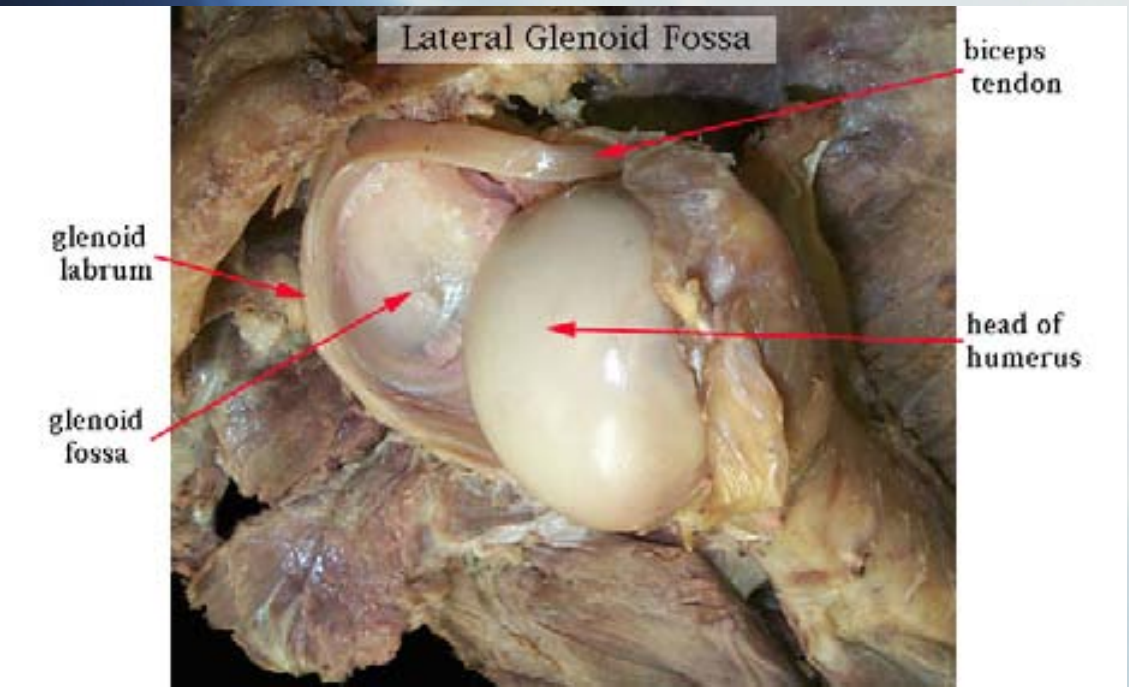

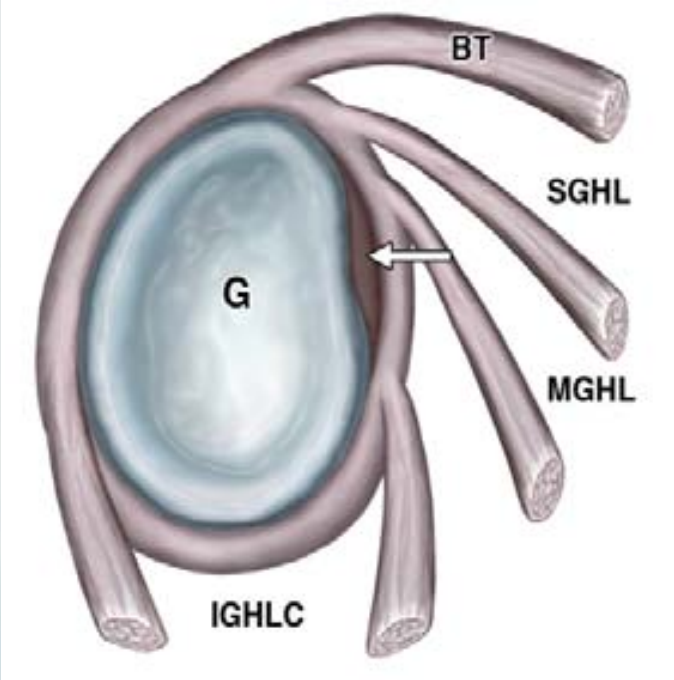

SLAP Tear

- **S**uperior **L**abrum tear from **A**nterior to **P**osterior
- Dull throbbing ache
- Shoulder discomfort during sleeping
  - Shoulder drops due to decreased stability. This pulls on muscles giving rise to discomfort.

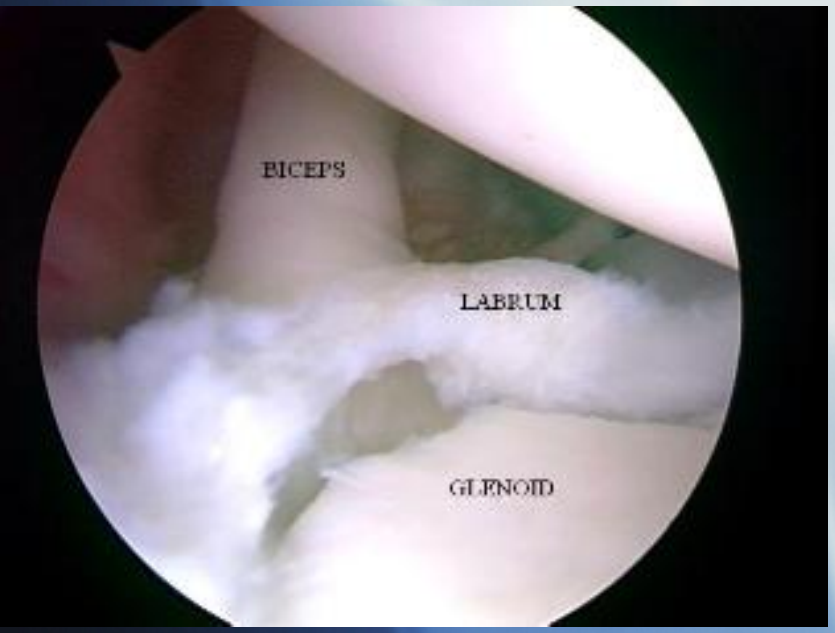

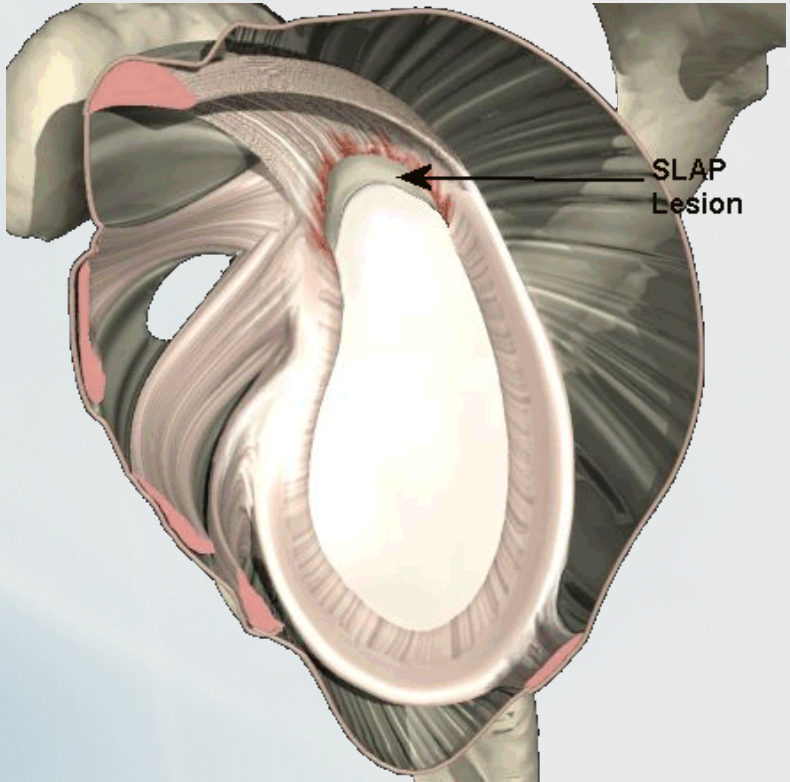

- Excessive extension and external rotation cause anterior joint dislocation.

Shoulder Musculature: Deep Layer

- **Rotator Cuff**
  - ***Abduct and rotate humerus; glenohumeral stabilisation*
    - Supraspinatus
      - Closed packed position
      - Initiation of humerus abduction
    - Infraspinatus
      - Most efficient external rotator of humerus
    - Teres minor
      - External rotation of humerus
    - Subscapularis
      - Internal rotation.

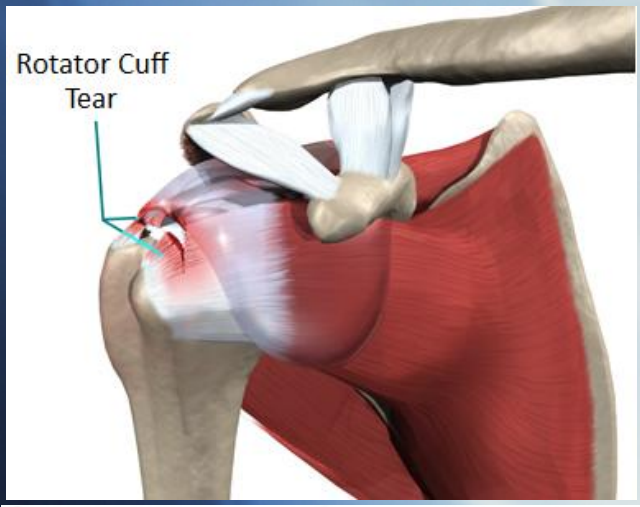

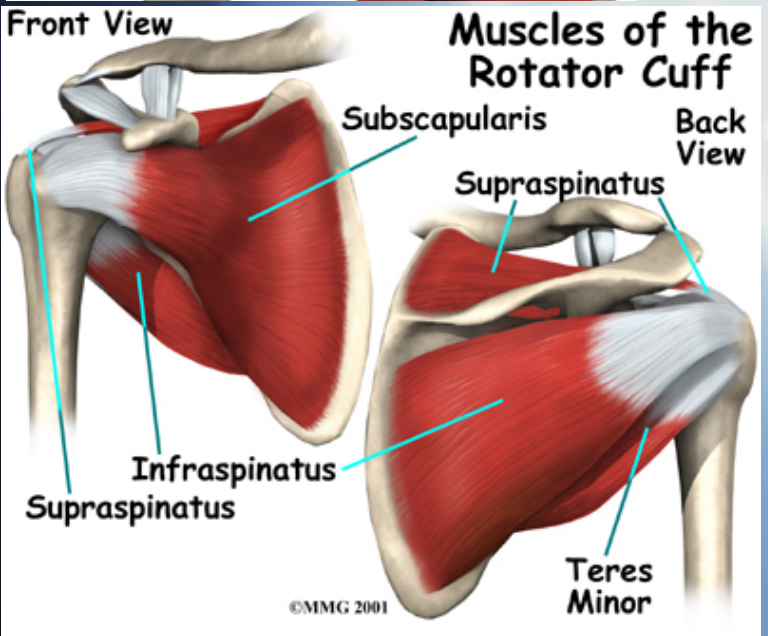

Shoulder Musculature: Outermost Layer

- Deltoid
  - Anterior fibres: abduction, flexion, internal rotation
  - Middle fibres: abduction
  - Posterior fibres: abduction, extension, external rotation

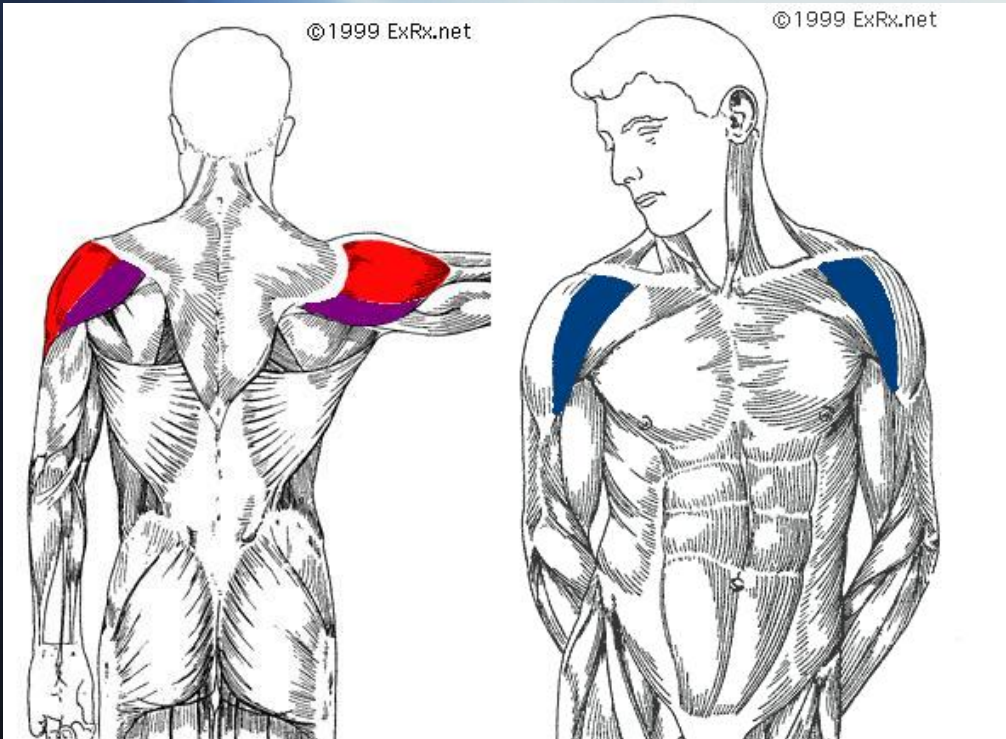

Shoulder Musculature: Outermost Layer

- Pectoralis major
  - Clavicular head
  - Sternocostal head

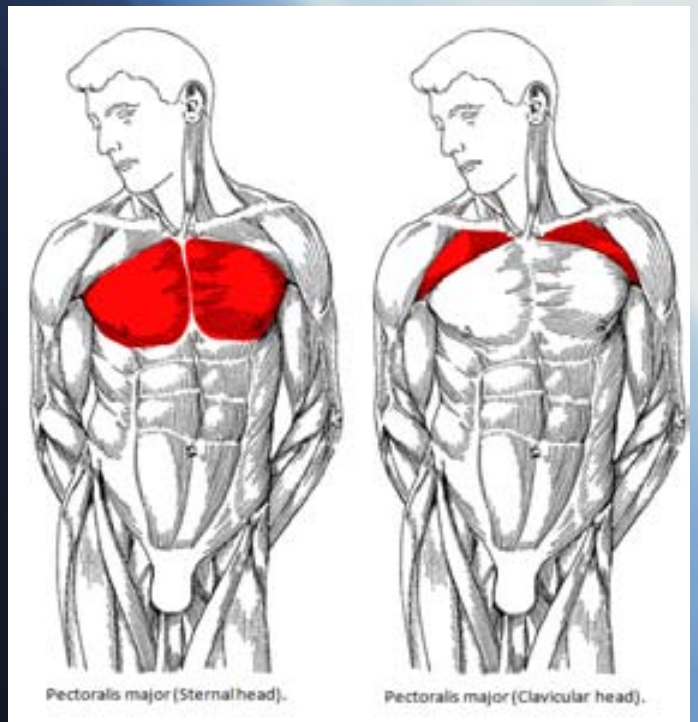

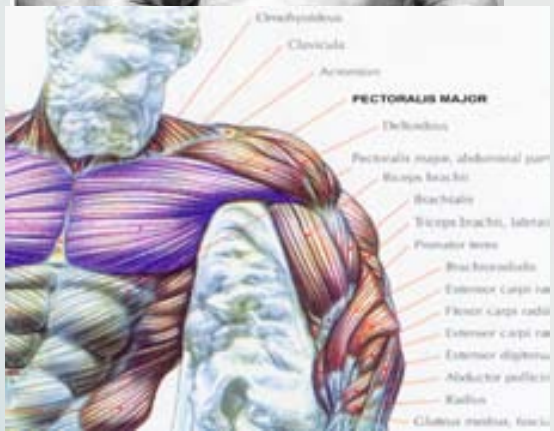

Shoulder Musculature: Outermost Layer

- Pectoralis minor
  - Important scapular stabiliser
  - Pulls scapula towards thorax (medial and inferior).

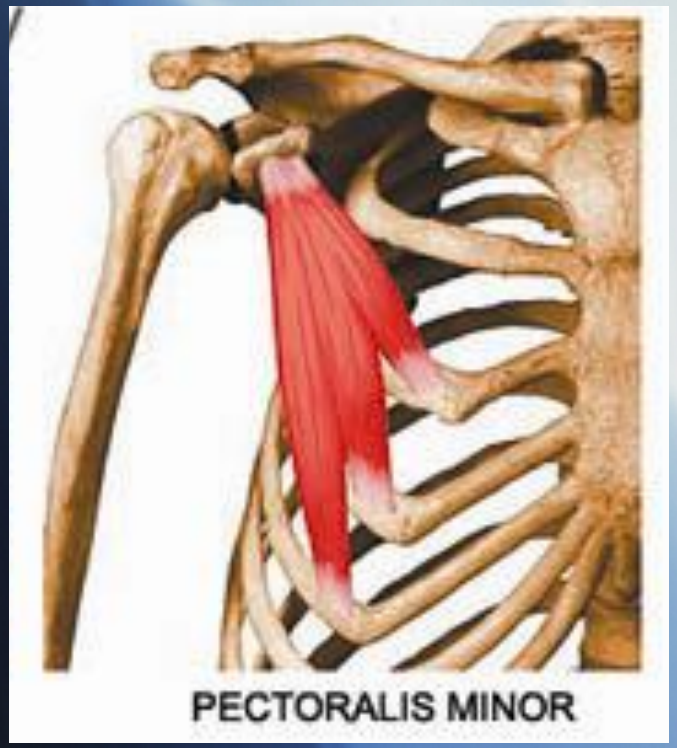

Shoulder Musculature: Accessory Muscles

- Trapezius
  - Upper fibres: Scapula elevation
  - Middle Fibres: Scapular adduction (retraction)
  - Lower Fibres: Scapular rotation

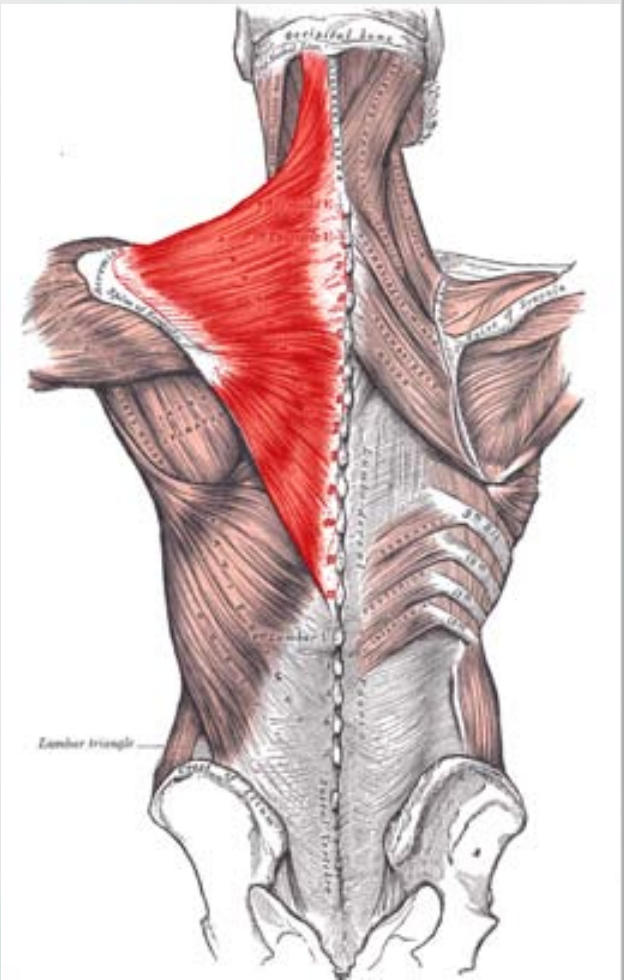

Shoulder Musculature: Accessory Muscles

- Rhomboid major/minor
  - Retract and rotate scapula
- Serratus anterior
  - Scapular protraction

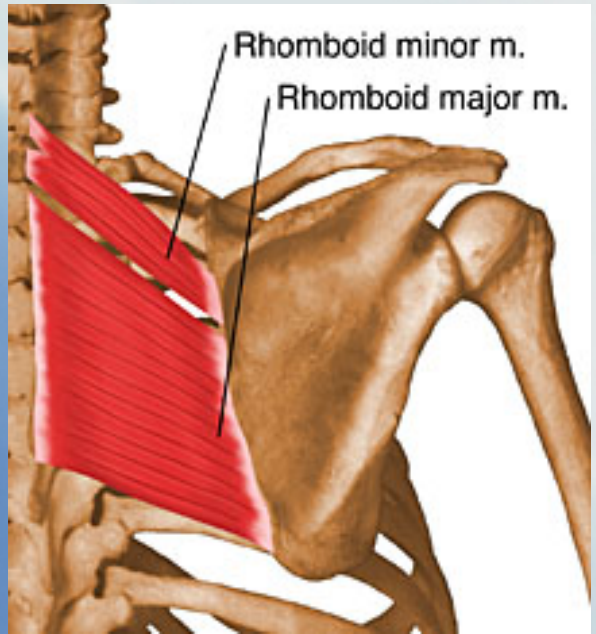

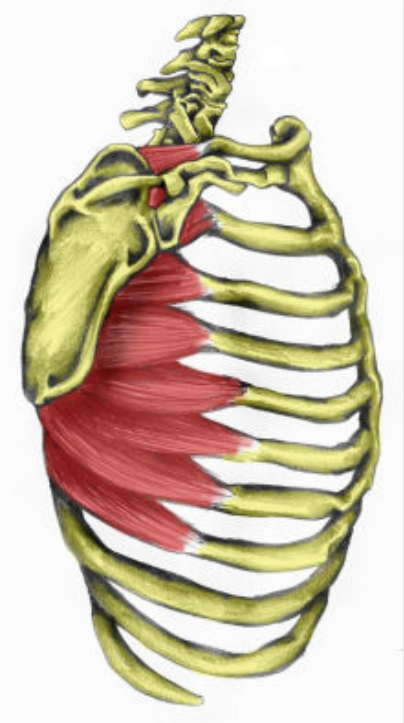

Shoulder Musculature: Accessory Muscles

- **Latissiumus dorsi**
  - Extension, adduction, and internal rotation
- **Teres major**
  - Adduction and internal rotation, extension

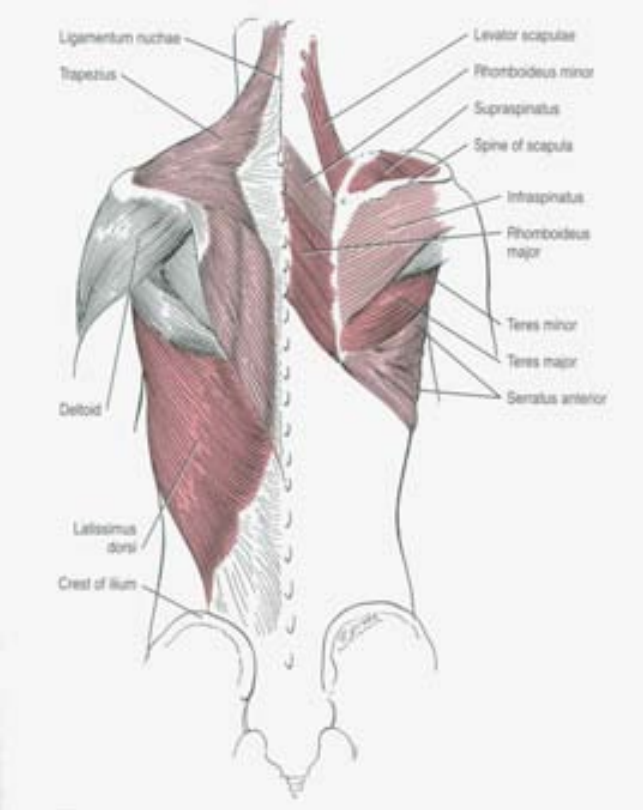

Shoulder Musculature: Accessory Muscles

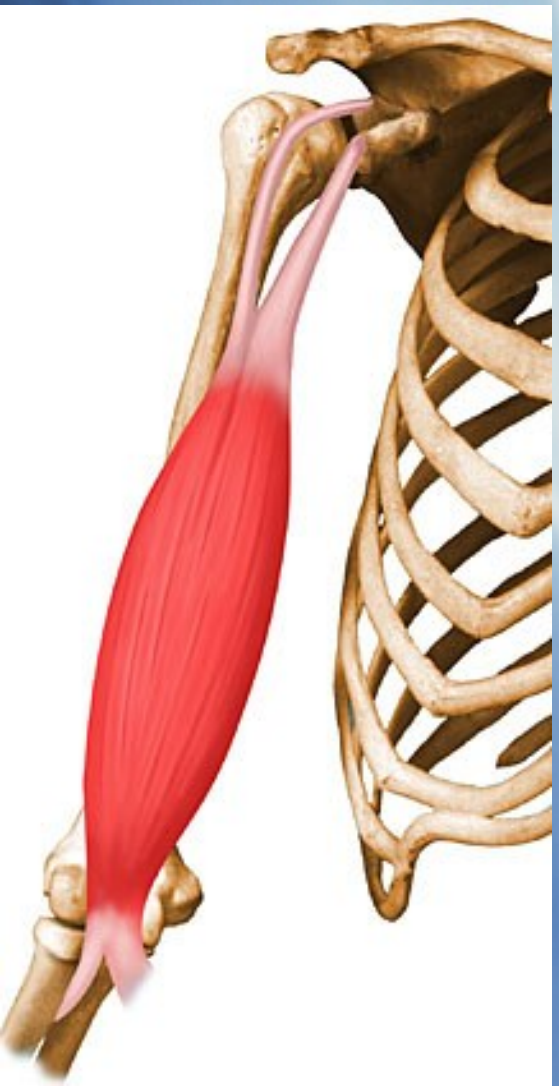

- **Biceps brachii**
  - Long head
    - Humeral head depressor confering stability.
  - Short head (coracoid process)
  - Shoulder flexion
  - Flexion and supination of forearm

Elbow

Elbow Movements

Elbow Movements

- Flexion-Extension
  - Normal range 0-146º
  - Functional range 30-130º

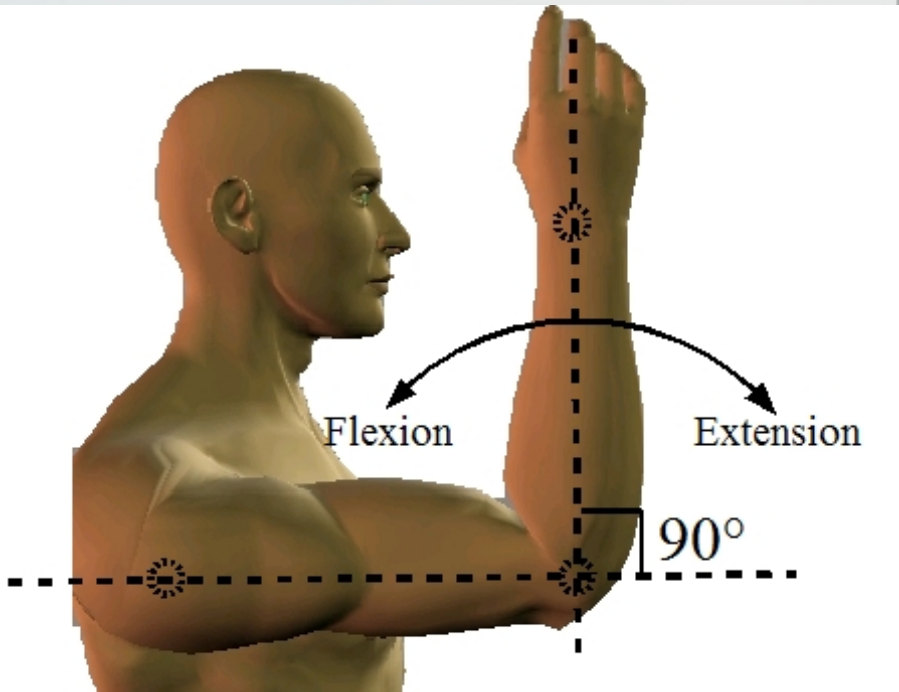

Elbow Movements

- Pronation-Supination
  - Normal range 71º pronation to 81º supination- 152º arc
  - Most activities require 50º pronation to 50º supination
  - Take place primarily at humoradial and proximal radioulnar joints.
  - Forearm rotates about a longitudinal axis passing through centre of capitulum.

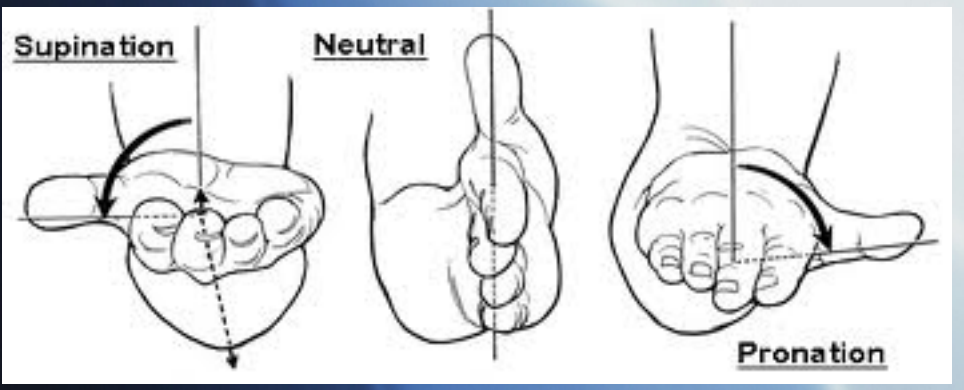

Distal Humerus

- Capitulum
- Trochlea
- Coronoid fossa
- Radial fossa
- Olecranon fossa
  - Lateral epicondyle
  - Medial epicondyle

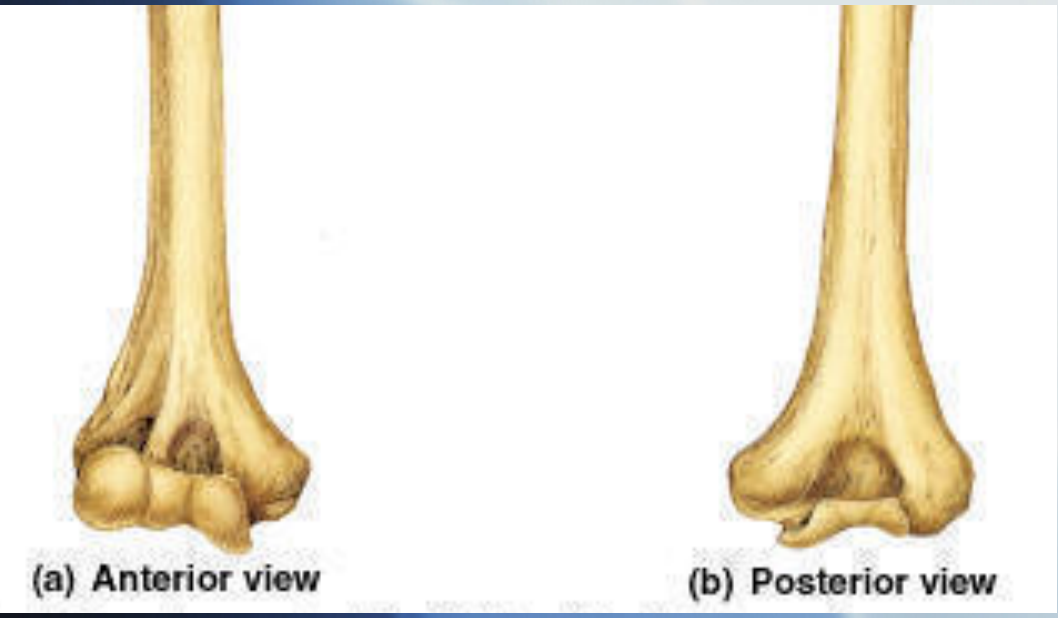

Elbow

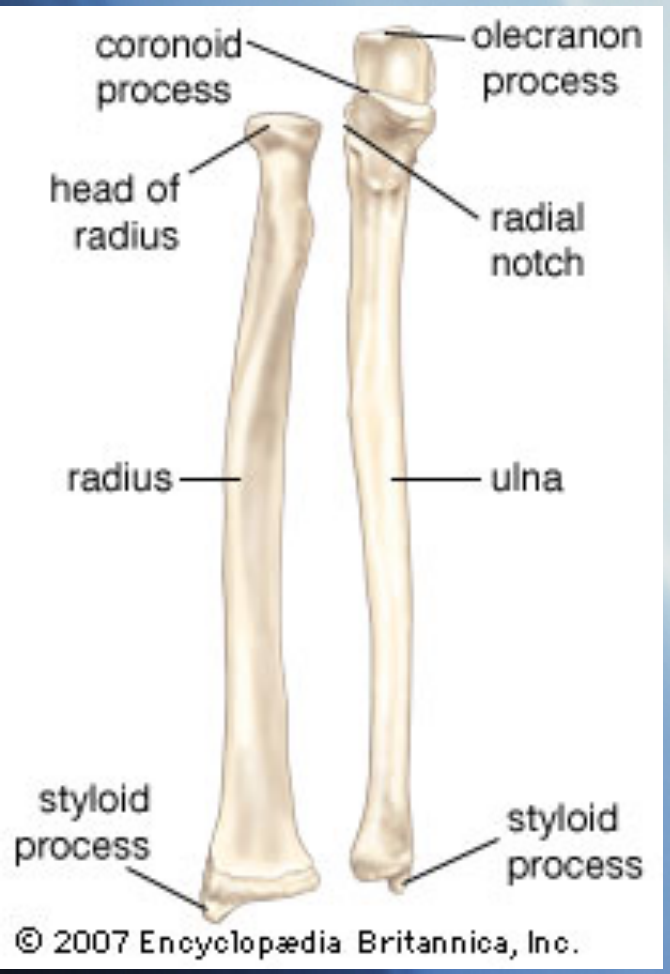

- Radius
  - Head and neck
  - Radial tuberosity
- Ulna
  - Olecranon
  - Coronoid process
    - Prevents posterior ulna displacement
  - Radial notch
  - Trochlear notch

Elbow Joint

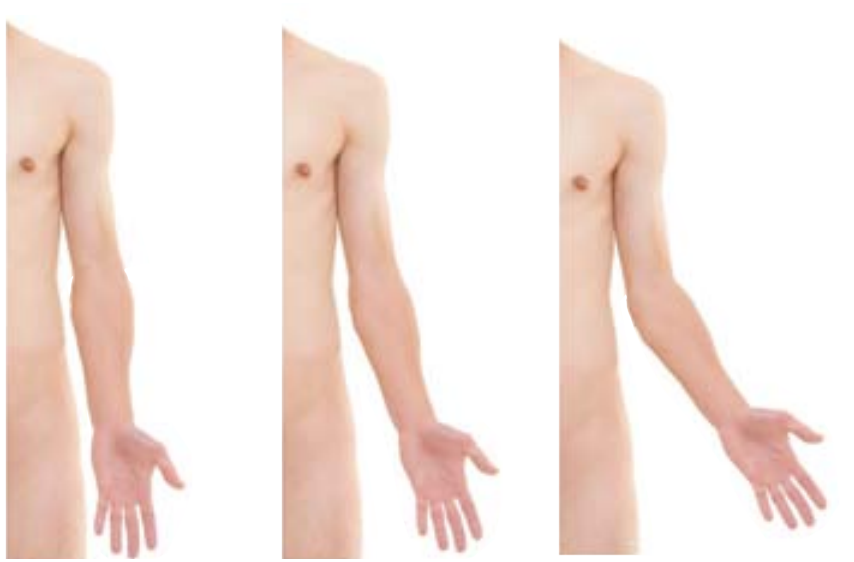

Varus Normal Valgus

- Varus vs. Valgus

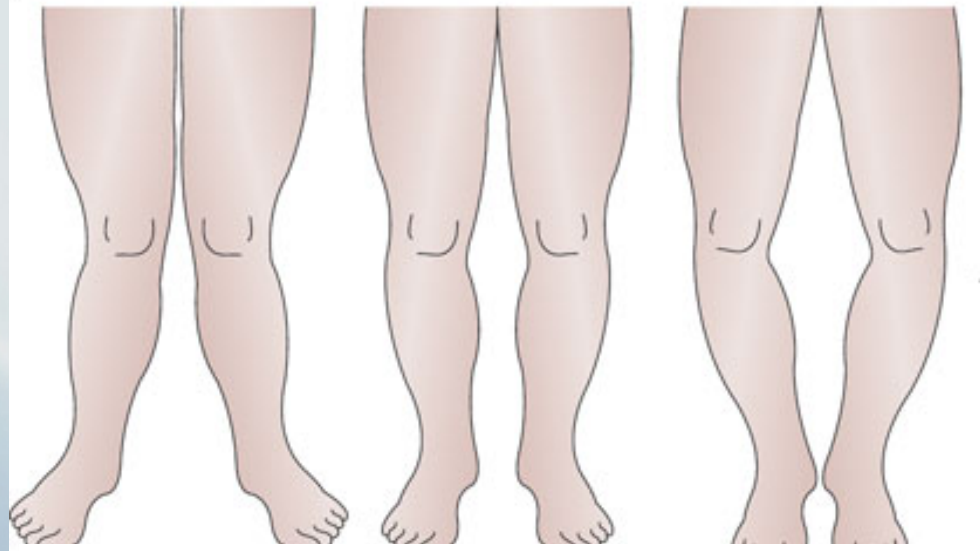

Valgus Normal Valgus

Elbow Joints

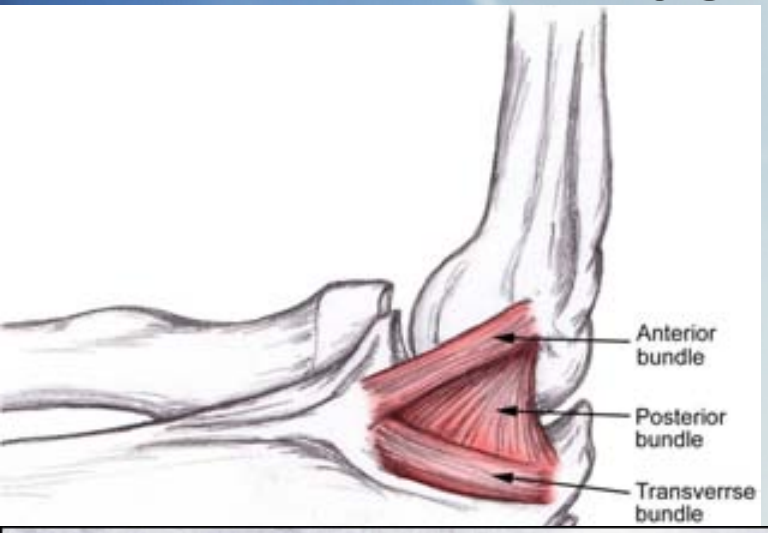

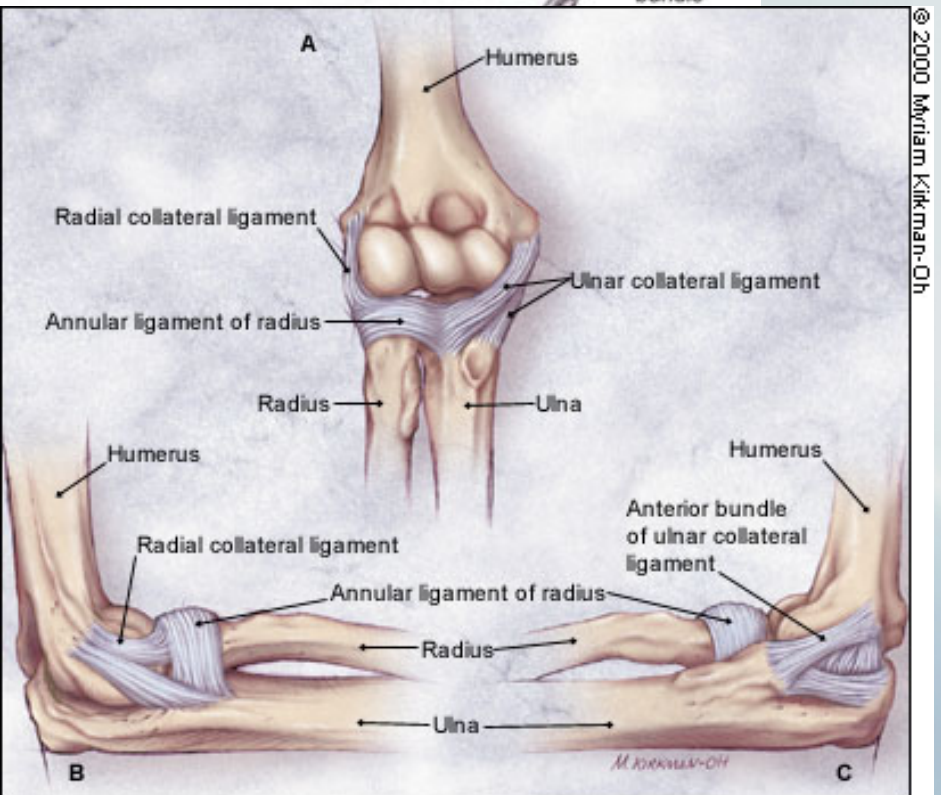

- **Humeroulnar joint**
  - Flexion-Extension
  - Ulnar (Medial) collateral ligament
    - Primary resistance to valgus stress
    - Anterior band: resists valgus forces, tightens in extension.
    - Posterior band: tightens in flexion
  - Elbow articulation resists varus stress.

Elbow Joints

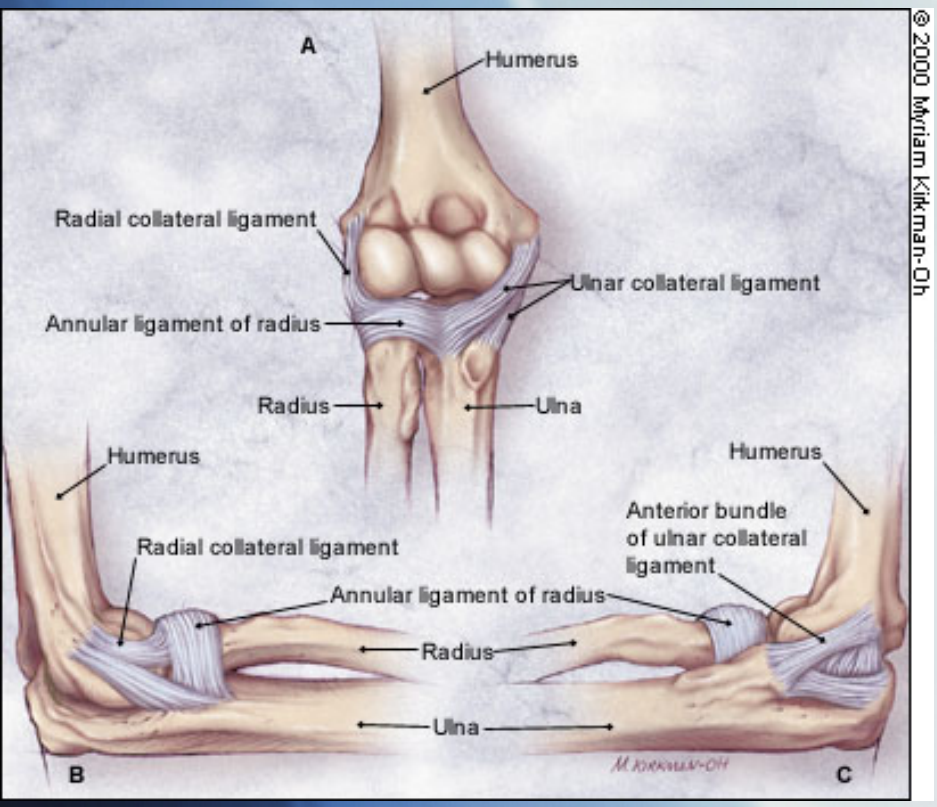

- **Humeroradial joint**
  - Flexion-Extension
  - Radial (Lateral) collateral ligament
    - Resists posterolateral rotation instability
  - Annular ligament
    - Resist subluxation of radial head

Radioulnar Joint

- Pronation-Supination

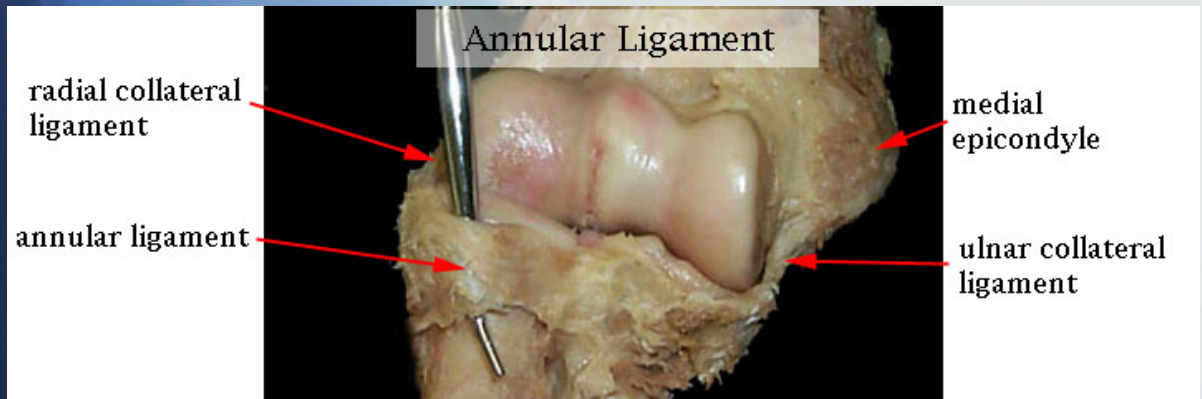

Elbow Musculature

Anterior Compartment (Flexion)

- Brachialis
  - Primary elbow flexor
- Brachioradialis
  - Active in both rapid and slow flexion

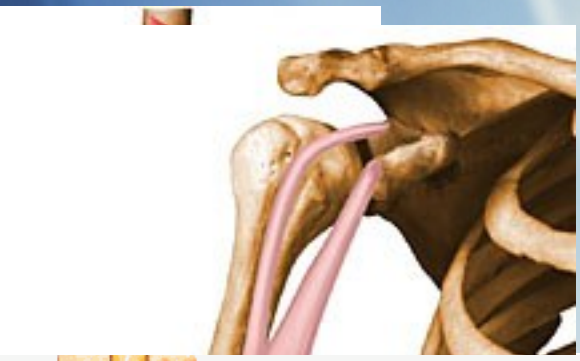

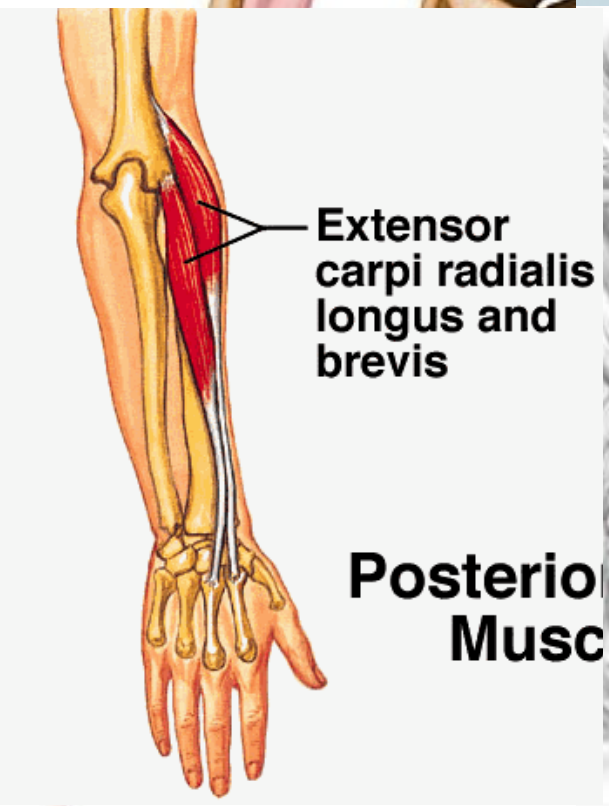

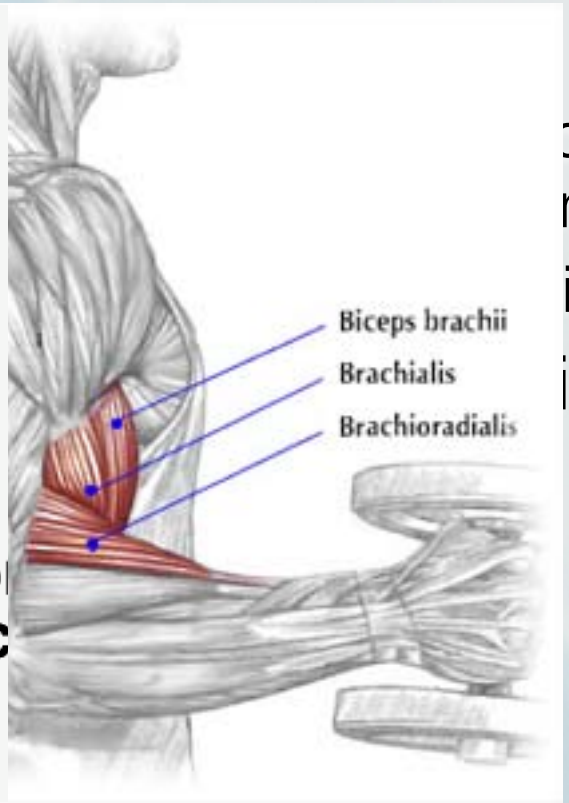

on with supinated or
m.

ing fast exercise.

i radialis longus/brevis

Posterio
Musc

Elbow Musculature

Posterior Compartment (Extension)

- Triceps brachii
  - Primary extensor (medial head primary, lateral and long heads act in reserve).
  - Three heads coalesce to form one tendon inserting on to olecranon process. Similar to quadriceps tendon on patella.

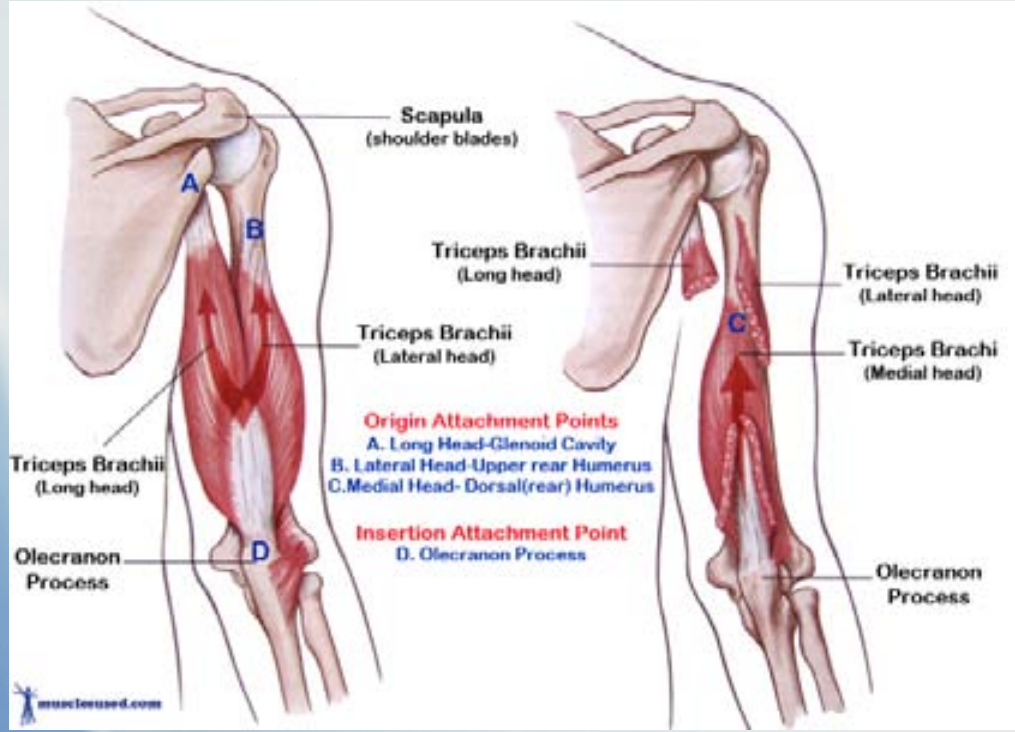

Valgus Elbow Orientation

- Extended Arm
  - Carrying angle (10-15°)
  - Less in children than adults, greater in females than males.
  - Allows arm swinging without contacting hips.
  - Greater resistance to valgus stress than to varus (Medial ulnar collateral ligament).
    - Valgus stress places joint into valgus, varus stress places joint into varus

Wrist and Hand

Wrist Anatomy

- Ulna
  - Styloid process
    - Styloid process of ulna connected to triquetral and pisiform bones by ulnar carpal ligament.
  - Triangular fibrocartilage

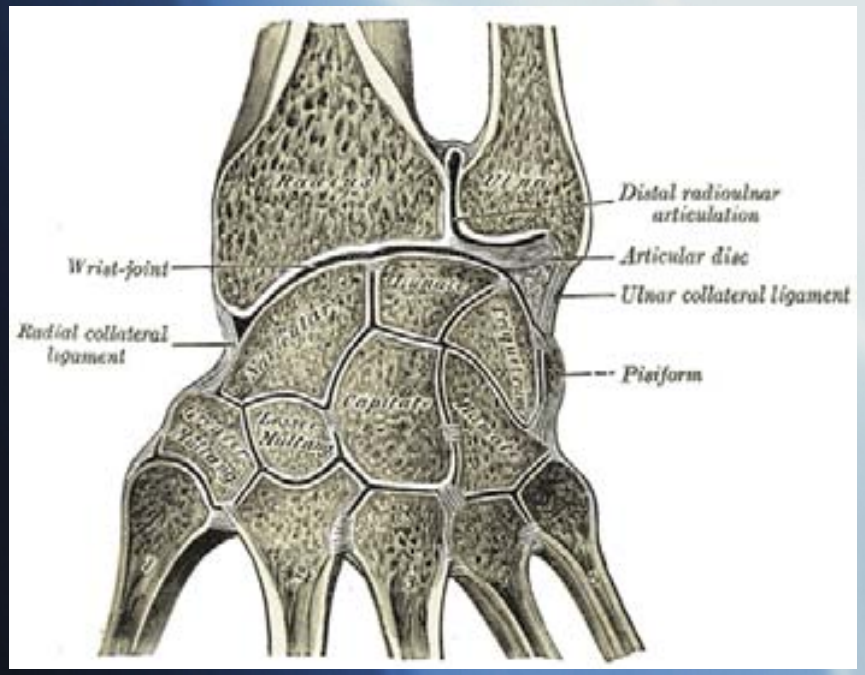

Wrist Anatomy

- Radius
  - Articulating surface for scaphoid and lunate
- Radioulnar joint
  - Head of ulna-ulnar notch on distal radius
  - Motion: Supination and pronation

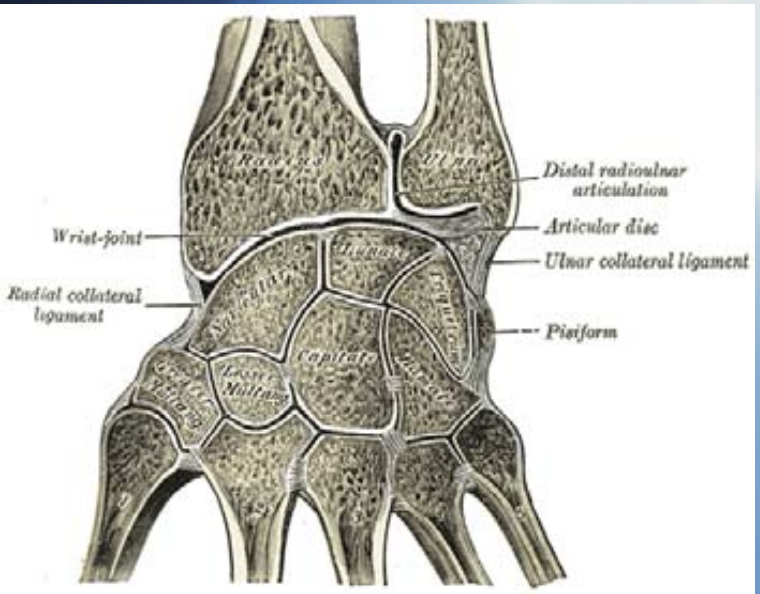

Wrist Anatomy

- Colle's Fracture
  - Complete transverse fracture within distal 2 cm of radius.
  - Distal fragment displaced dorsally.
  - Results from forced dorsiflexion (fall from outstretched limb)
  - Dinner fork deformity

Wrist Anatomy

- Carpals
  - Proximal Row
    - Moveable
    - Scaphoid
    - Lunate
    - Triquetrum
    - Pisiform
      - Within flexor carpi ulnaris tendon- enhances mechanical advantage.

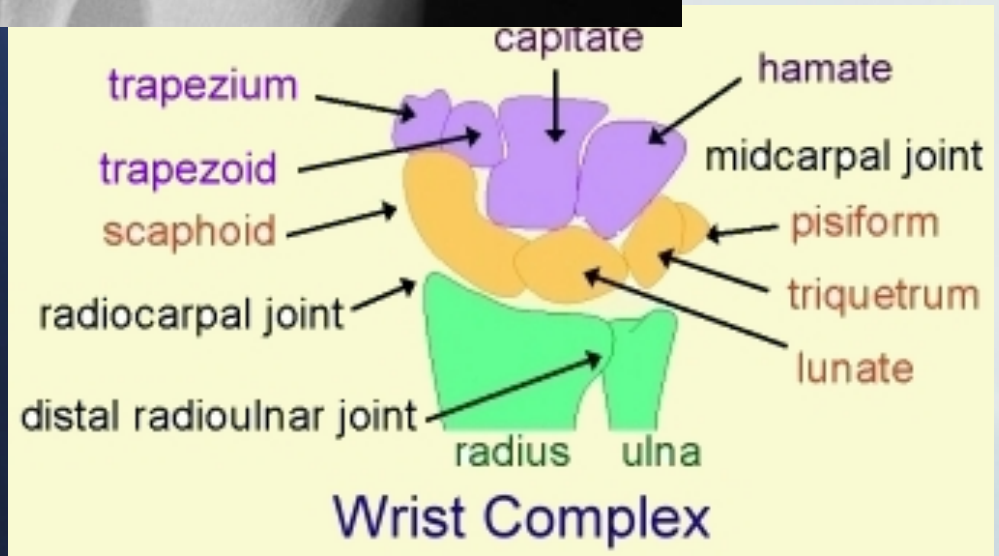

Wrist Anatomy

- Carpals
  - Distal Row
    - Immobile
    - Trapezium
    - Trapezoid
    - Capitate
    - Hamate

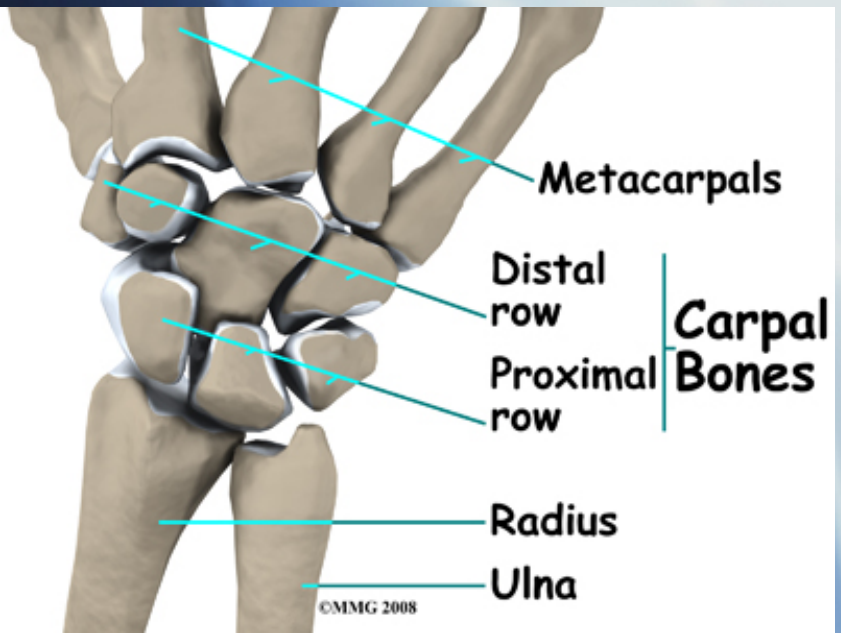

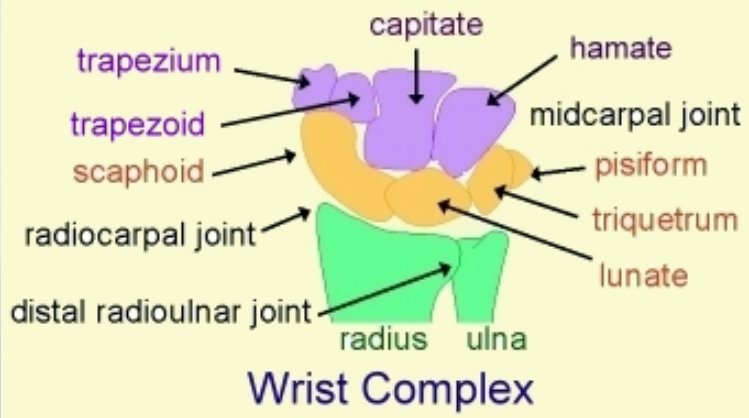

Hand Anatomy

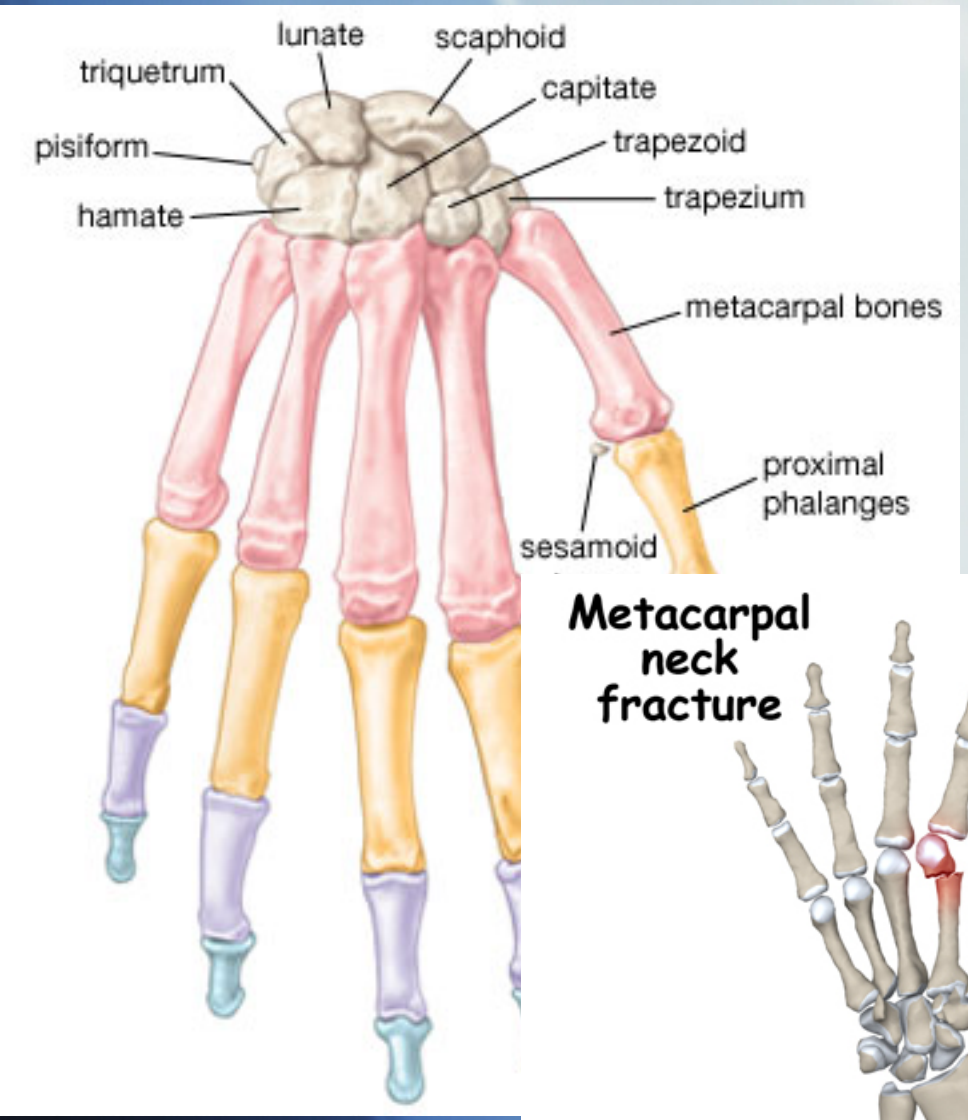

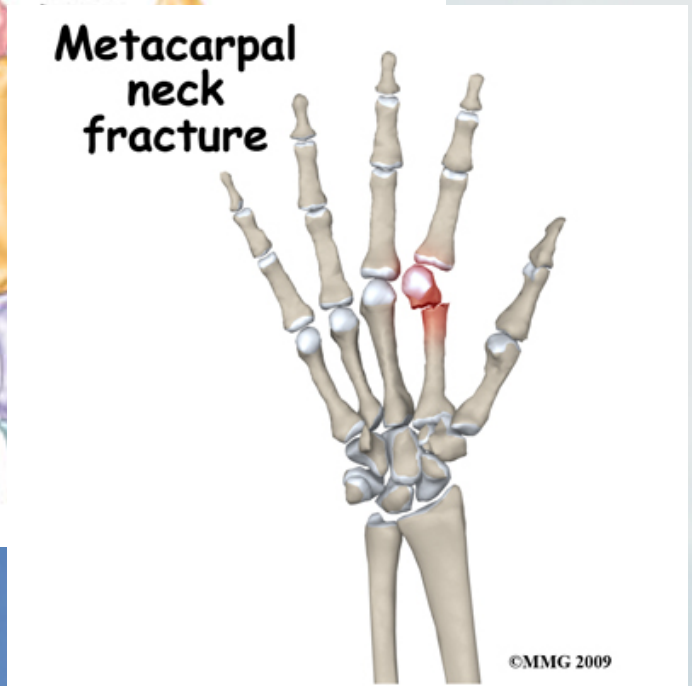

- Metacarpals
  - I-V
  - Head
  - Neck
- Phalanges
  - Proximal
  - Intermediate
  - Distal

Hand Anatomy

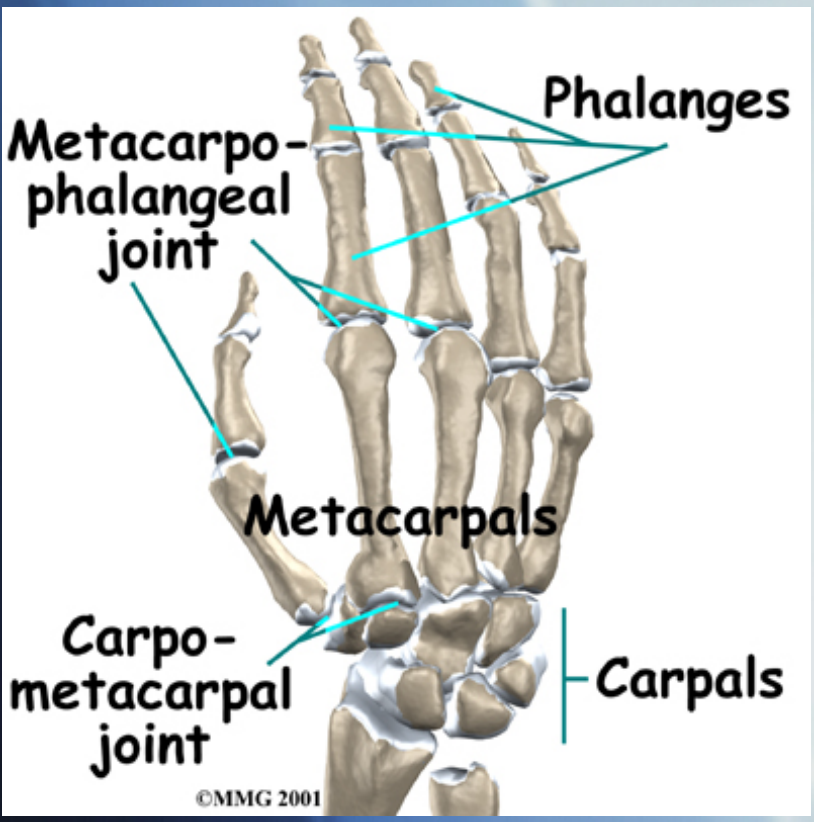

- Joints
  - Carpometacarpal (CMC) Joints
  - Metacarpophalangeal (MCP)Joints
  - Interphalangeal
    - Proximal Interphalangeal Joint (PIP)
    - Distal Interphalangeal Joint (DIP)
- Digital articulations all designed to function in flexion.

Arches of the Hand

- Intrinsic hand muscles maintain arches
- Proximal Transverse
  - Capitate as keystone
  - Relatively flexed
  - Along immobile distal carpal row
- Distal Transverse
  - Head of 3rd metacarpal as keystone
  - Passes through all the metacarpal heads
  - More mobile

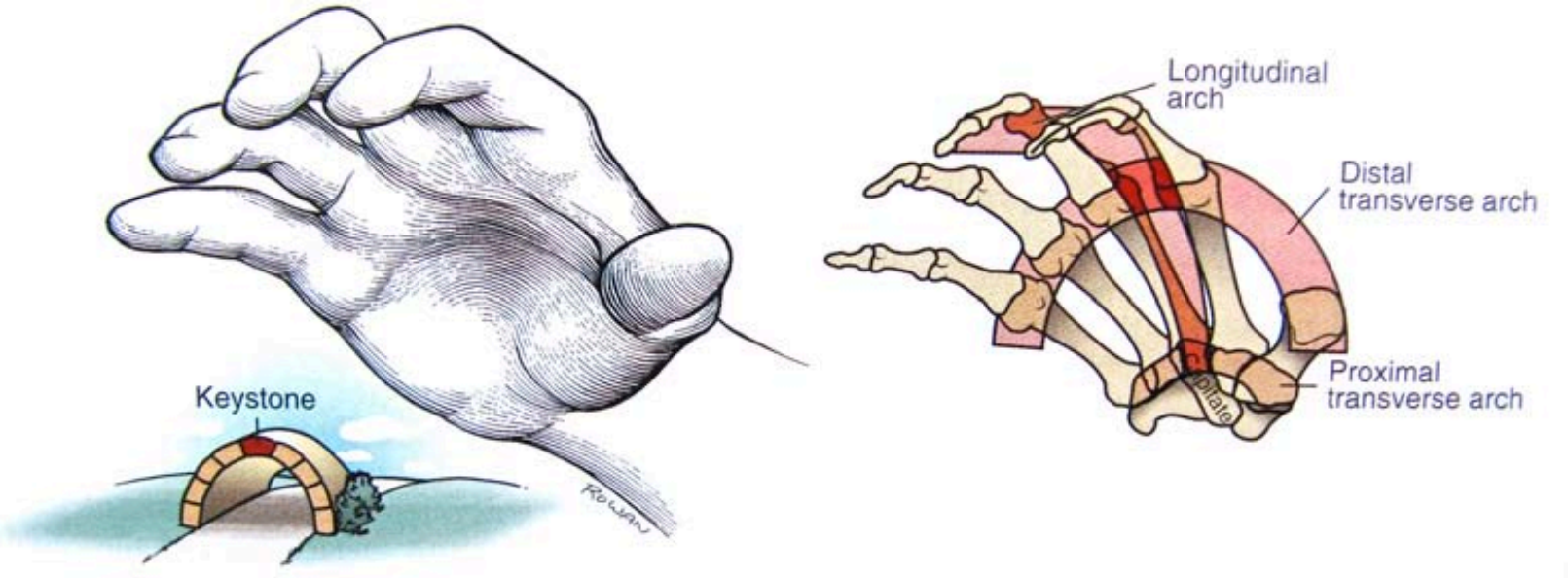

Arches of the Hand

- Longitudinal
  - Connects transverse arches.
  - Central pillar- 2nd and 3rd metacarpals
  - Thumb- 4th, 3rd-5th finger flexion allows palm to flatten or cup.
    - Try this! Cup hand and move index finger

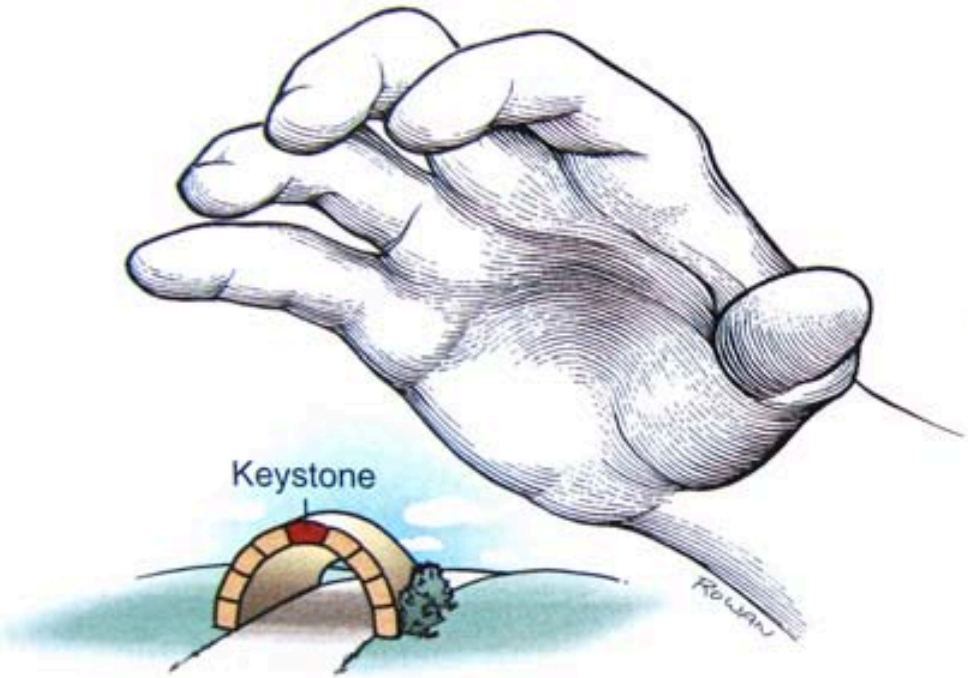

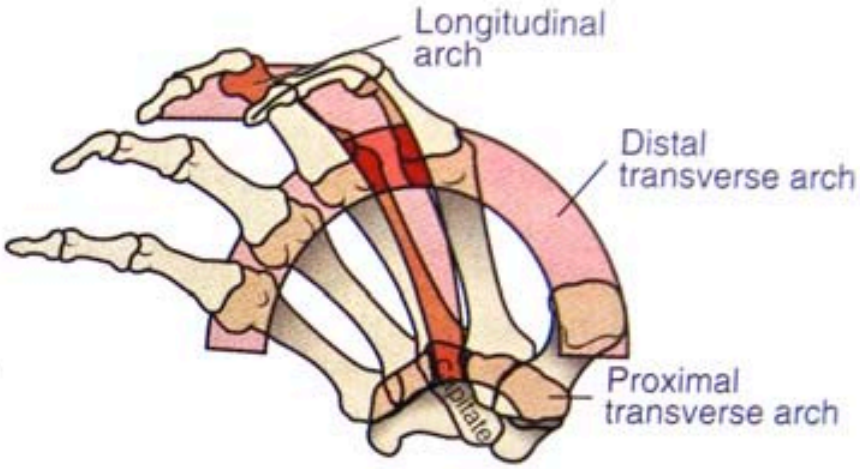

Arches of the Hand

- Similar to foot
  - Two longitudinal arches and 1 transverse arch.
  - Hand more transverse (opposition)-foot more longitudinal-foot flexion-extension.

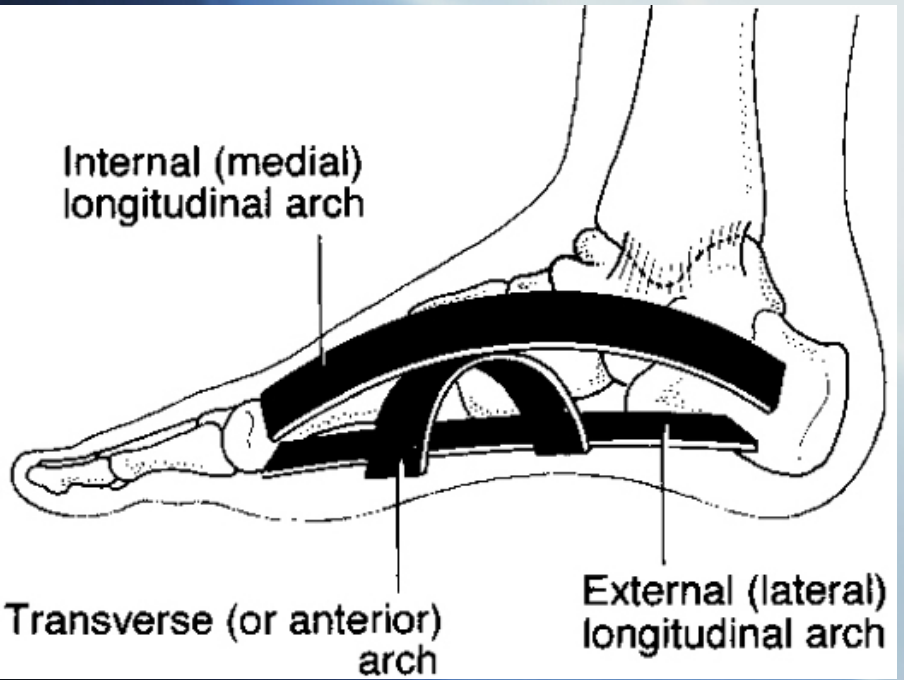

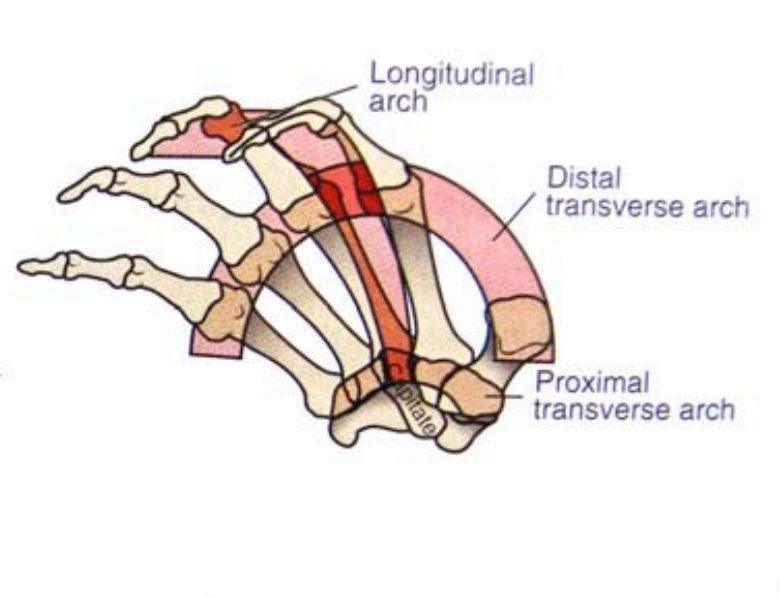

Muscles at the Wrist

- Motors of the wrist
  - Flexor carpi radialis, Flexor carpi ulnaris, Palmaris longus
  - Extensor carpi radialis longus/brevis, Extensor carpi ulnaris
  - Control radial/ulnar deviation as well as flexion/extension.

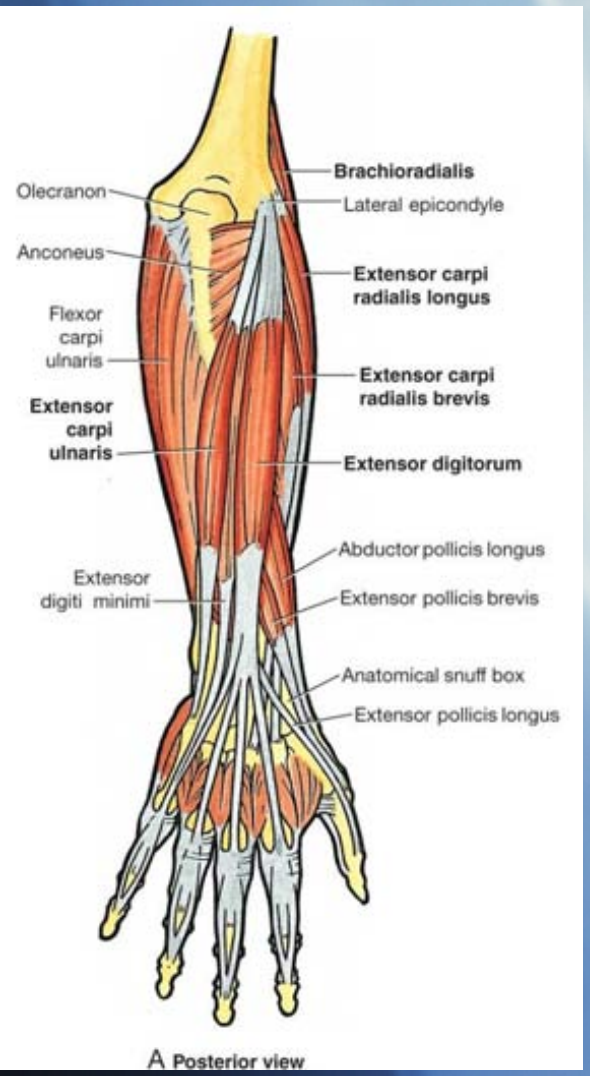

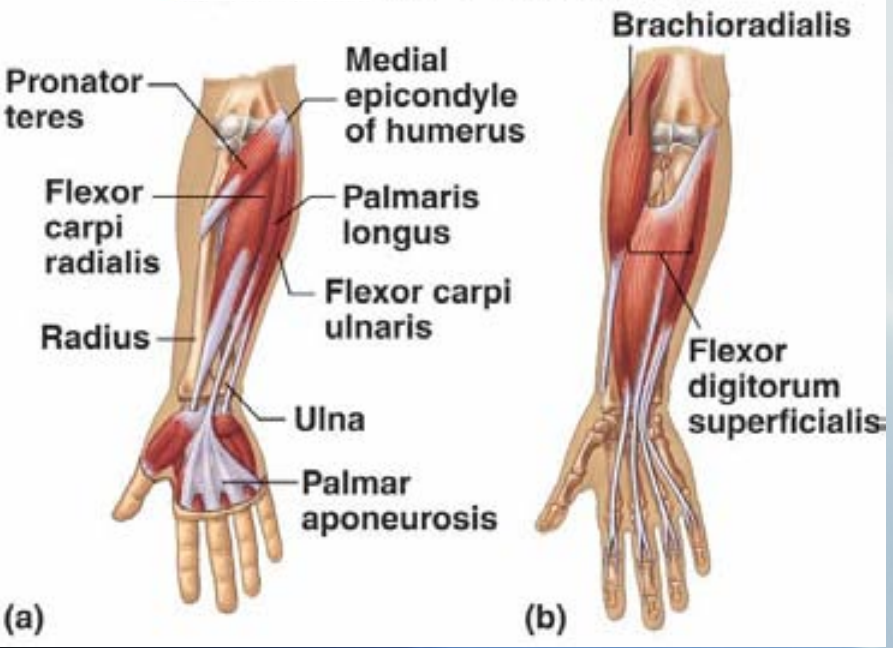

Anterior Compartment

- Flexor carpi radialis
  - Flex and abduct hand at wrist
- Flexor digitorum superficialis
  - Flex intermediate phalanx
  - Continued action flexes 1st phalanx at hand
  - Flexes hand at wrist, forearm at elbow
- Flexor digitorum profundus
  - Flex distal phalanx after passing through tendon of FDS
  - Flex hand at wrist

Muscles at the Wrist

- Test FDS and FDP independently
  - If DIPs can flex but PIPs cannot, there is a problem with FDS.

Anterior Compartment

- Palmaris longus
  - Flex hand at wrist
- Flexor carpi ulnaris
  - Flex and adduct hand at wrist
- Flexor pollicis longus

Posterior Compartment

- Brachioradialis
  - Assists elbow flexion
  - Semipronator/semisupinator of forearm (bring to neutral position)

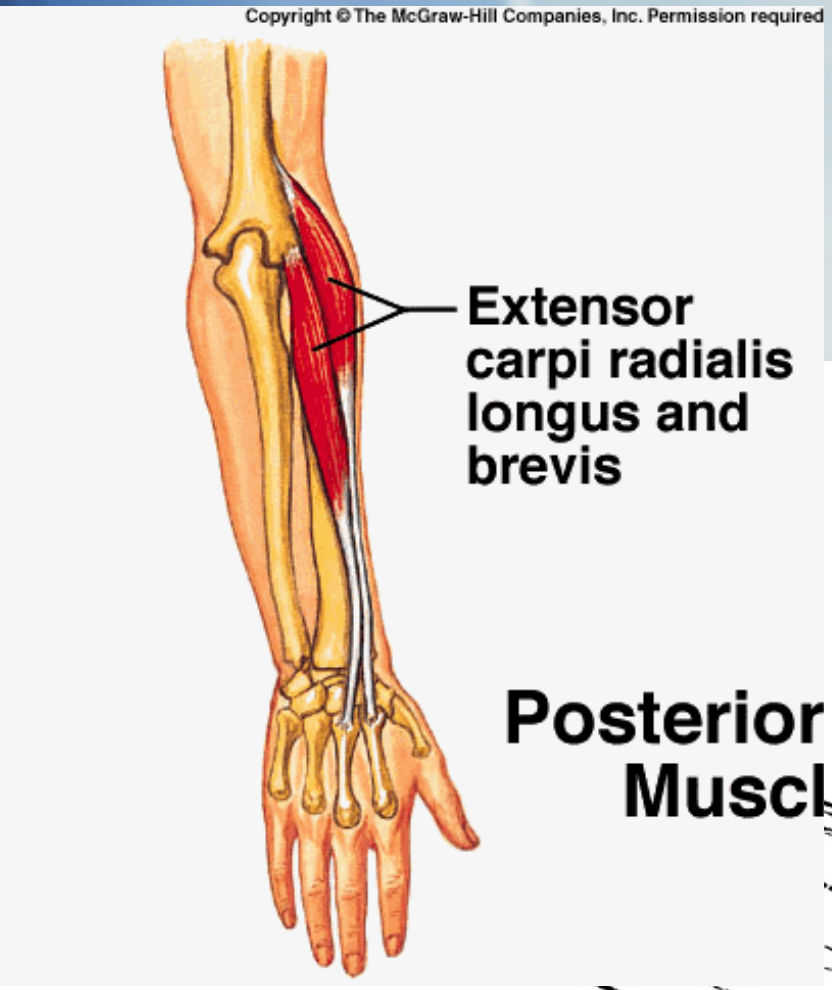

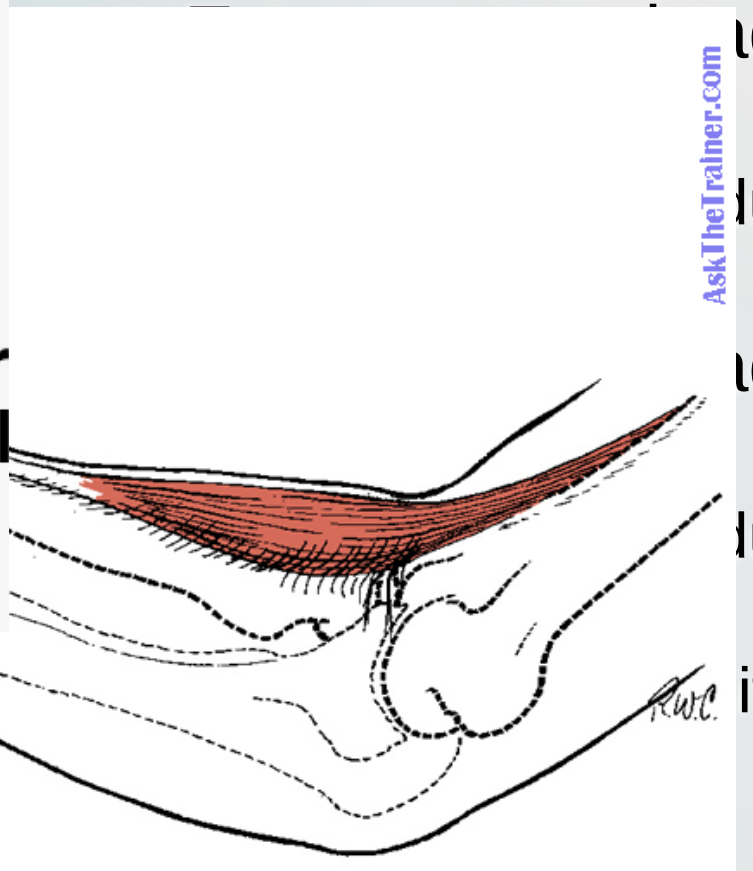

adialis

ducts hand

adialis

ducts hand

iflexor.

Posterior Compartment

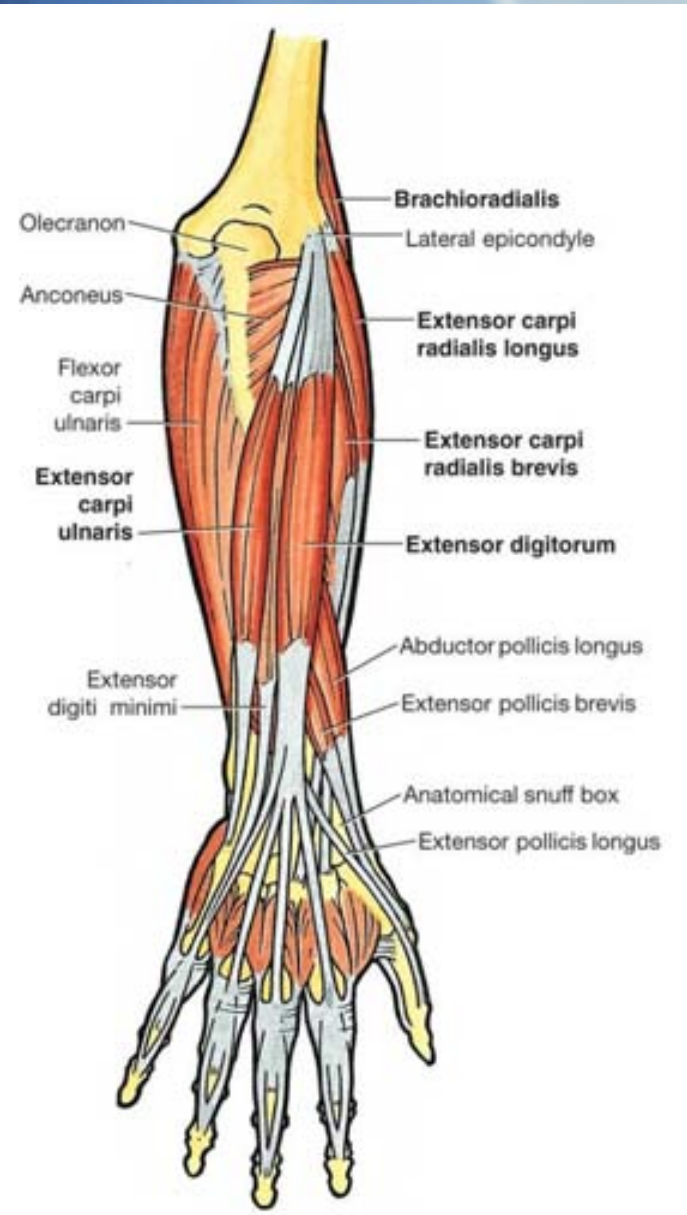

A Posterior view

- Extensor digitorum
  - Extends MCP and CMC joints
- Extensor digiti minimi
  - Extend proximal phalanx of 5th digit at MCP
  - Assist in hand extension at wrist
  - Extend middle and distal phalanges of 5th digit when proximal phalanx flexed.
- Extensor carpi ulnaris
  - Extends and adducts hand at wrist

Posterior Compartment

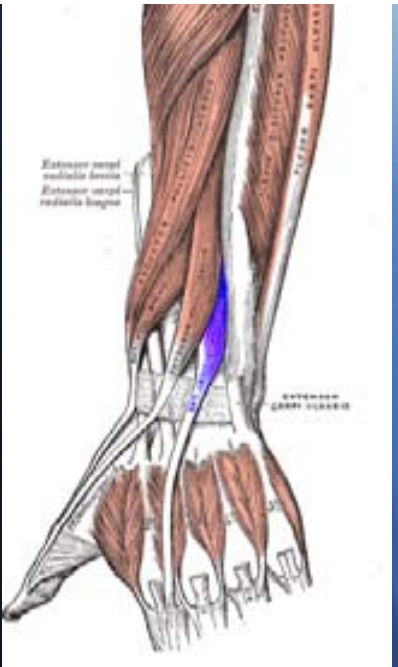

- Abductor pollicis longus
  - Flex and abduct wrist
  - Abducts and assists thumb CMC flexion
- Extensor pollicis brevis
  - Extends proximal phalanx of thumb
- Extensor pollicis longus
  - Extends distal thumb phalanx
- Extensor indicis
  - Extension of all phalanges of index finger.

Wrist Movements

- **Flexion:**
  - FDS/FDP, Flexor carpi radialis, Flexor carpi ulnaris, palmaris longus, flexor pollicis longus.
- **Extension:**
  - Extensor carpi radialis longus/brevis, extensor carpi ulnaris, extensor digitorum, extensor digiti minimi, extensor indicis, extensor pollicis longus.

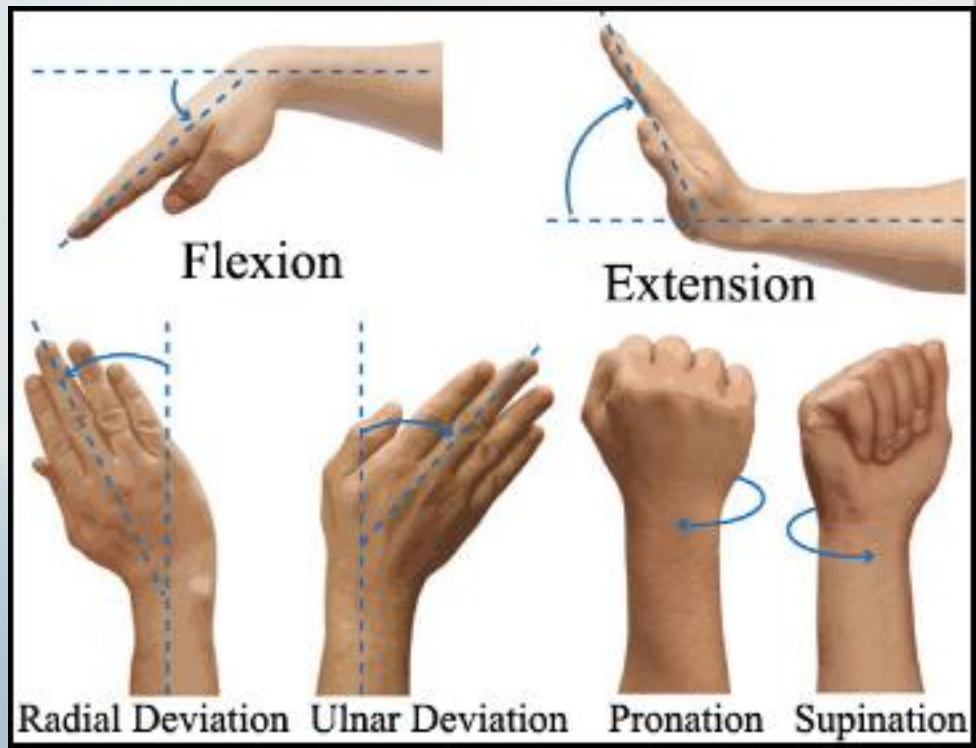

Wrist Movements

- Ulnar Deviation (Adduction):
  - Flexor carpi ulnaris, Extensor carpi ulnaris
- Radial Deviation (Abuction):
  - Flexor carpi radialis, extensor carpi radialis longus/brevis, abductor pollicis longus, extensor pollicis longus/brevis.

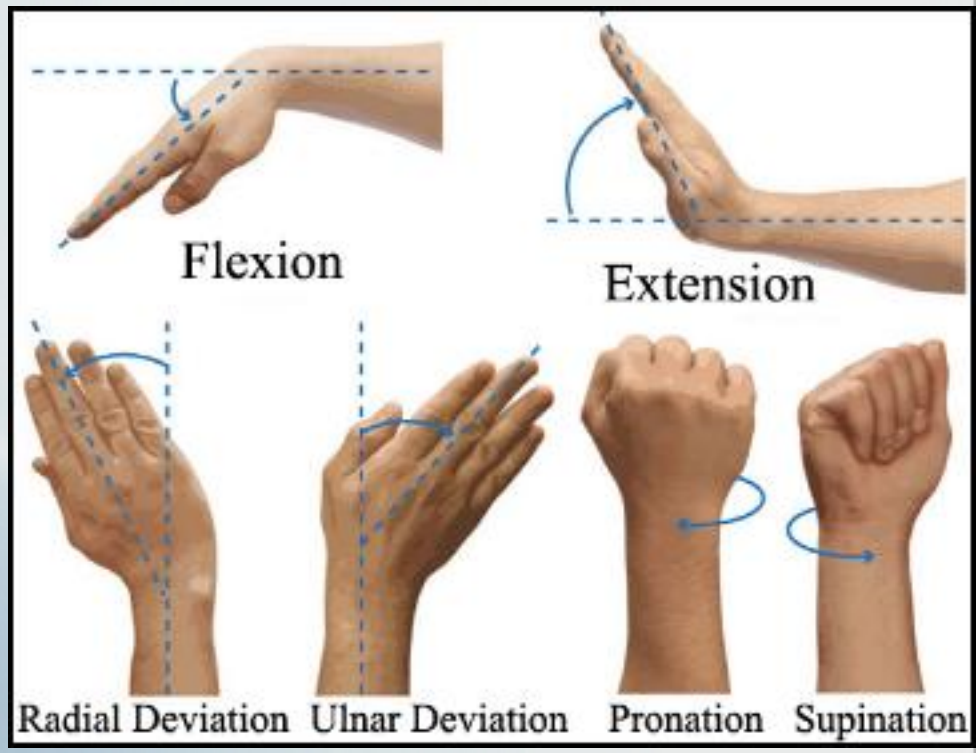

Thumb Movements

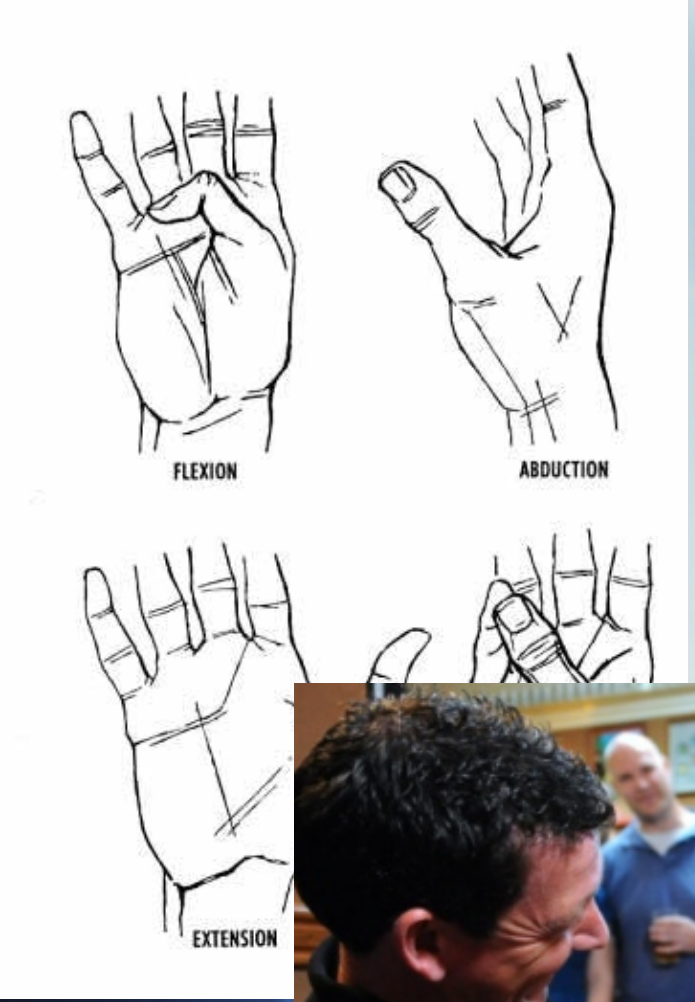

- Flexion
- Extension
- Abduction
- Adduction
- Opposition

Intrinsic Hand Muscles: A of A of A

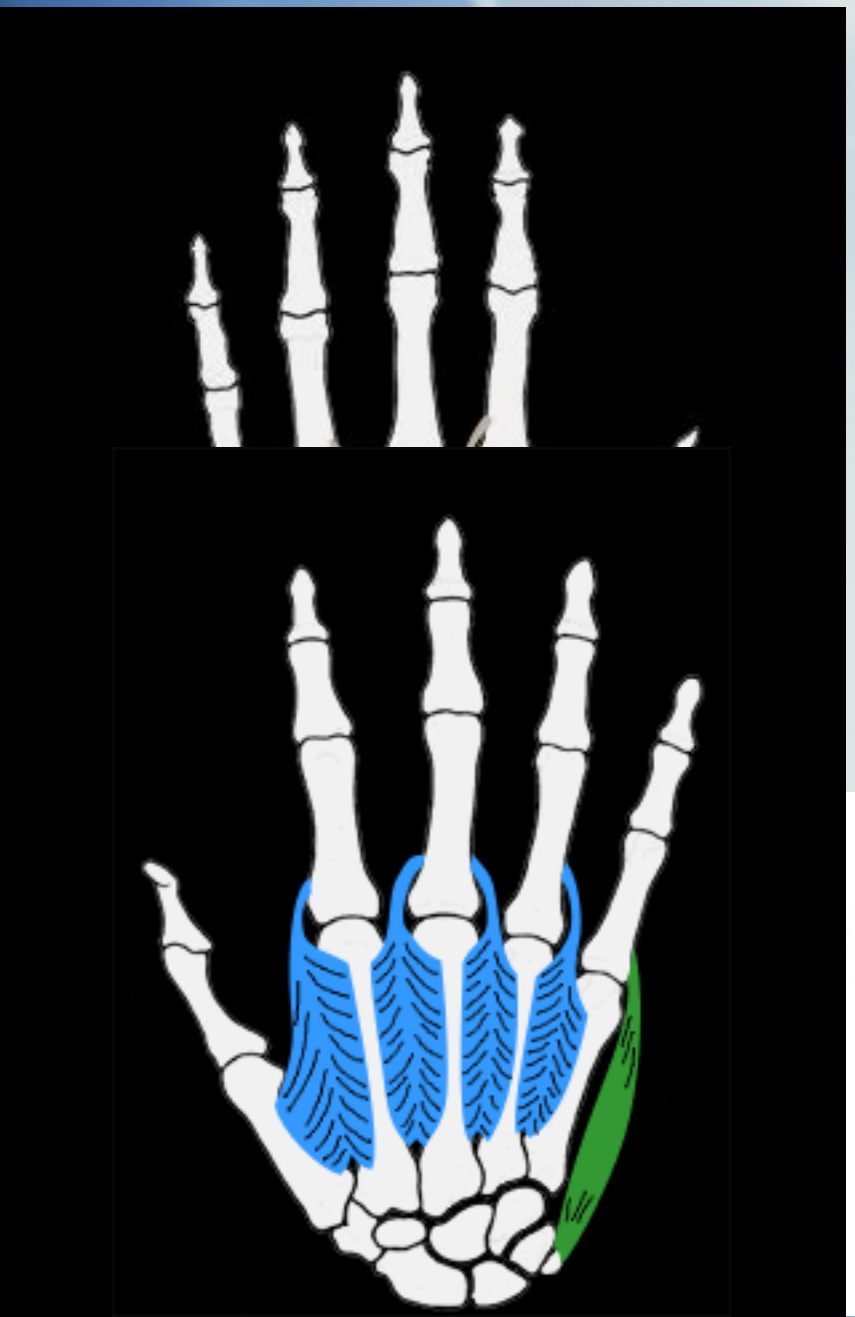

Deep Musculature:

- Lumbricals:
  - Flex MCP joints
  - Extend IP joints
- Palmar Interossei:
  - Adduct digits towards middle finger.
  - PAD
- Dorsal Interossei:
  - Abduct digits away from middle finger.
  - DAB

Intrinsic Hand Muscles: A of A of A

- Interossei and lumbricals in writing
  - Lumbricals place digits into writing position (flex MCP-Extend IP joints)
  - Interossei adduct or abduct digits to make width of letters.

Grip

- **Power Grip**
  - Fingers flexed at all three joints
  - No thumb reinforcement
  - Usually performed with ulnar deviation and extension of wrist.
- **Coal hammer Grip**
  - Thumb is wholly occupied in reinforcing clamping action of digits (bunched fist).

Grip





- **Precision Grip**
  - Manipulation of small objects between thumb and flexor aspects of fingers.
  - Fingers semi-flexed.
  - Thumb palmar abducted and opposed.
- **Muscles**
  - Adductor pollicis (adducts thumb)
  - 1st dorsal interosseus (abducts index finger)
  - Lumbrical (flex MCP joint)
  - Opponens pollicis
  - Flexor pollicis brevis
  - FDS/FDP

Grip

- Dynamic Tripod
  - Thumb, index finger, and middle finger for precision handling of an object.
  - 4th and 5th digits used for support and static control.

Grip

- Hook Grip
  - Fingers flexed so their pads lie directly parallel and slightly away from palm.
  - Requires relatively little muscle activity.
  - Used when precision not needed but power needed over a long period of time.
  - Ie. Carrying a suitcase by its handle.
  - Only grasp pattern available when hand intrinsics not working.
    - Paralysis of hand intrinsics- hand relies on hook grasp for all functional task

Brachial Plexus (5-3-6-3-5)

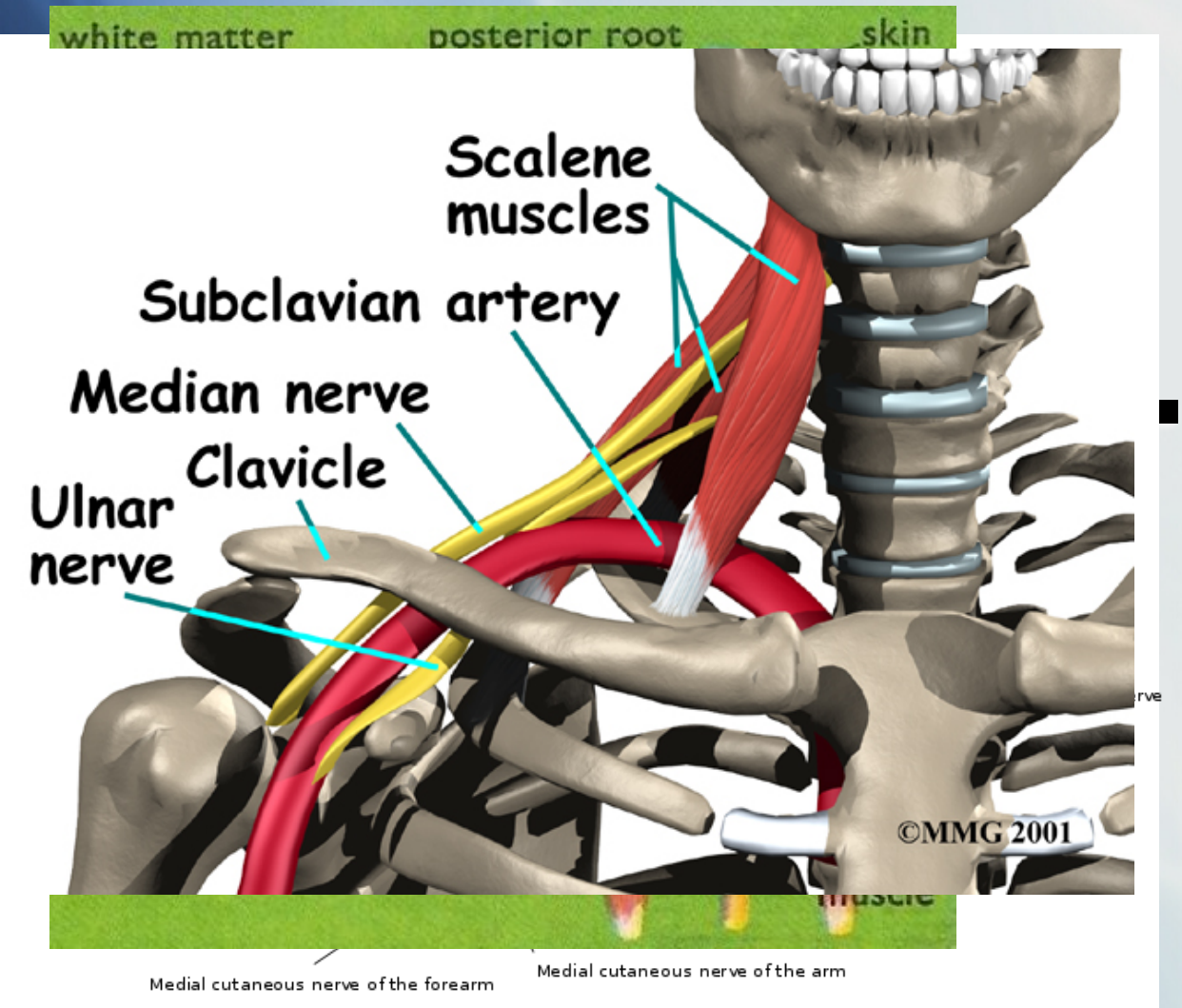

- 5 Roots
  - From anterior (ventral) rami of spinal nerves
  - Scalene muscles
- 3 Trunks
  - Superior (C5-C6)
  - Middle (C7)
  - Inferior (C8-T1)

Brachial Plexus

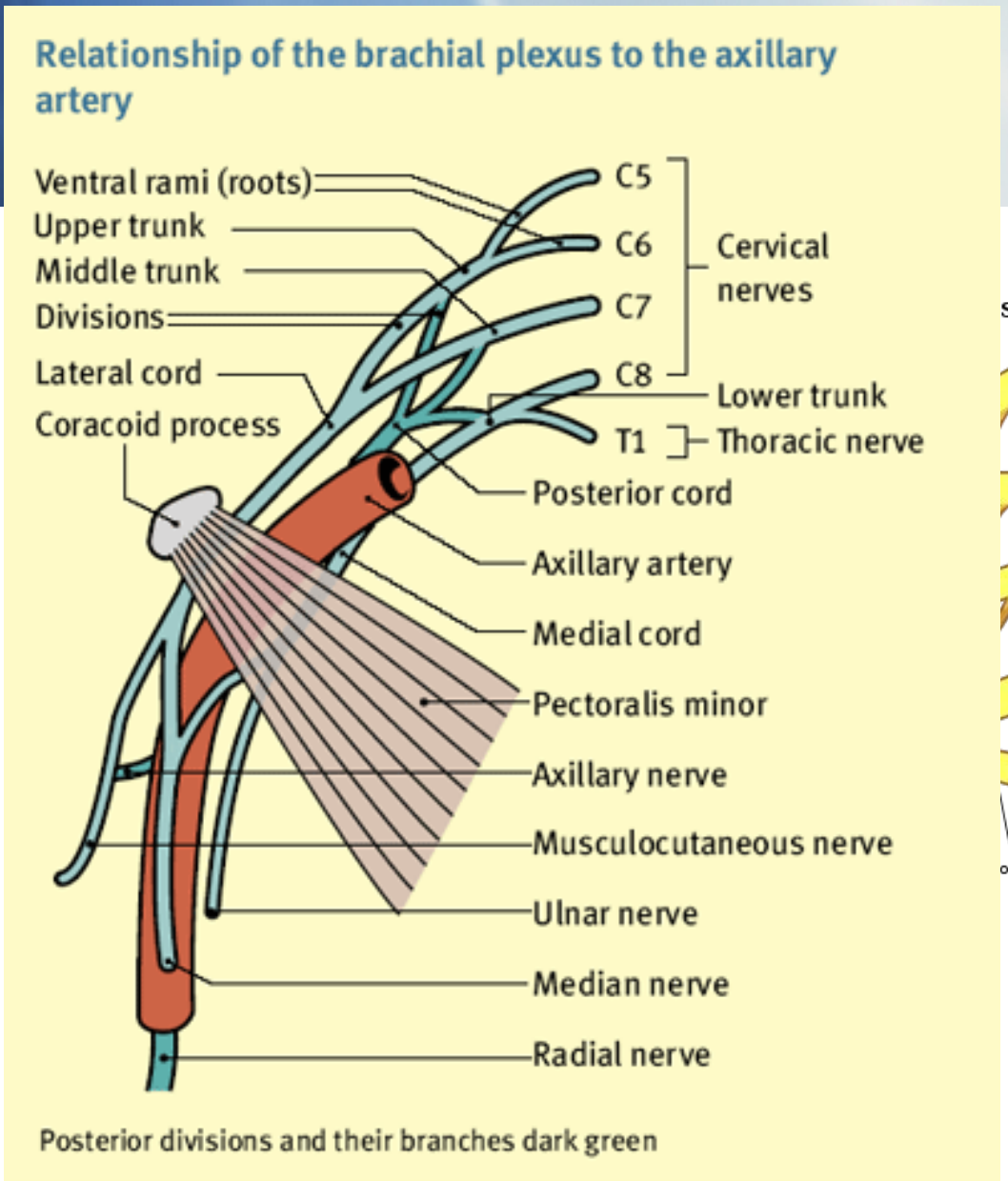

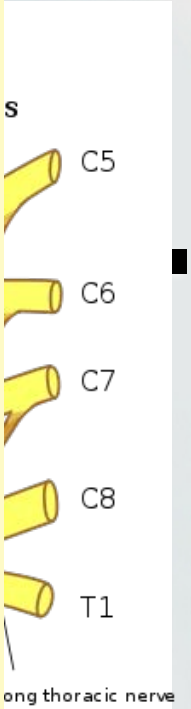

- 6 Divisions
  - Each trunk splits into anterior and posterior
- 3 Cords
  - Posterior (C5-T1)
  - Lateral (C5-C7)
  - Medial (C8-T1)
  - Named in reference to axillary artery

us Branches

- Axillary nerve (C5-C6)
- Musculocutaneous nerve (C5-C7)
- Median nerve (C5-T1)
- Ulnar nerve (C8-T1)
- Radial nerve (C5-T1)

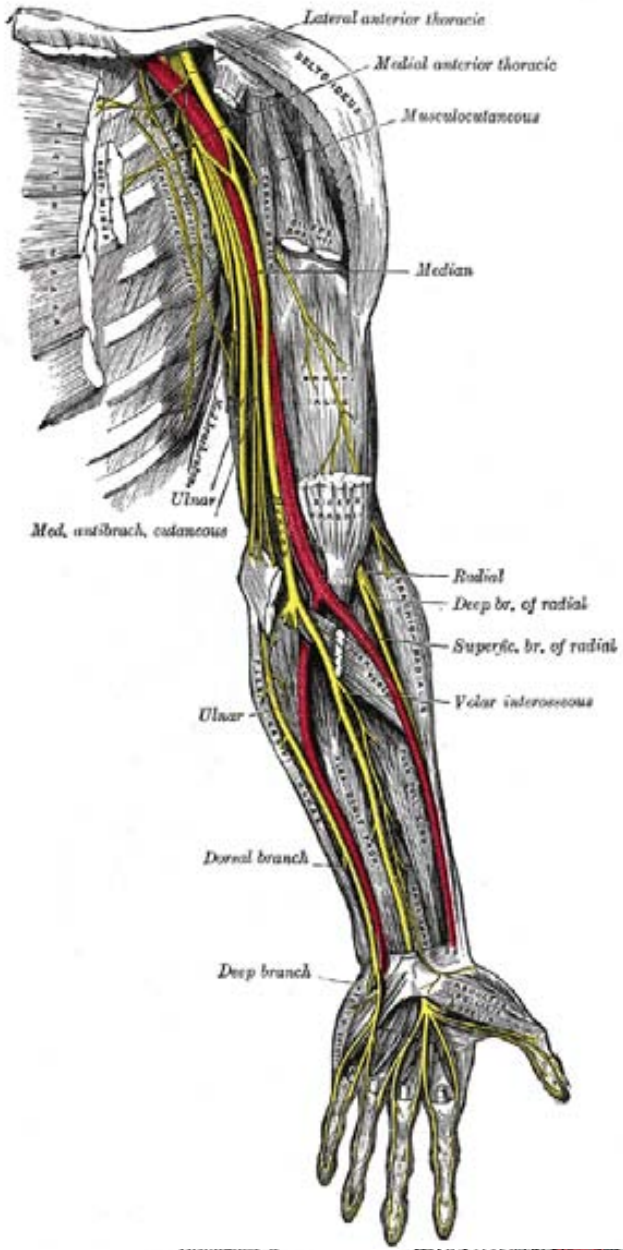

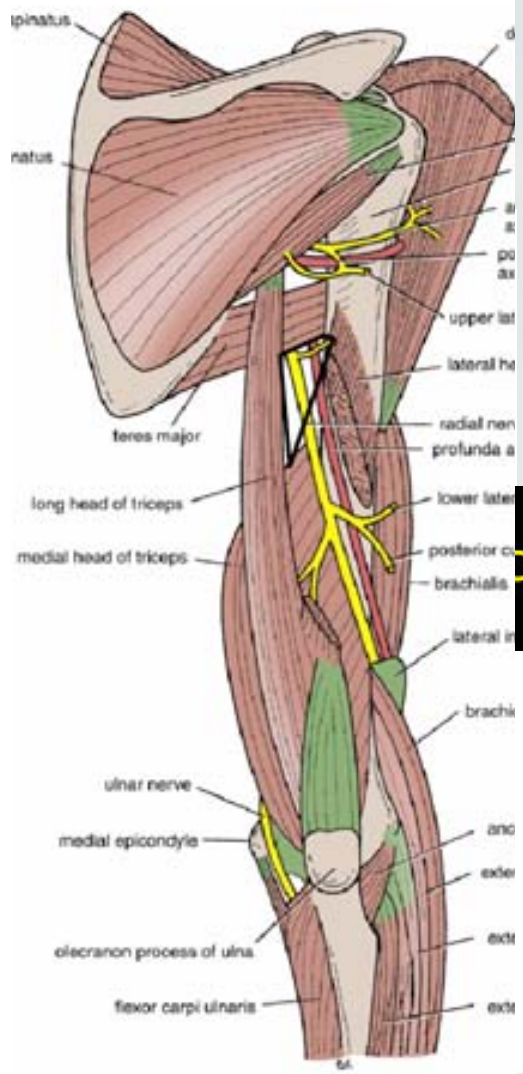

cutaneous

Brachialis

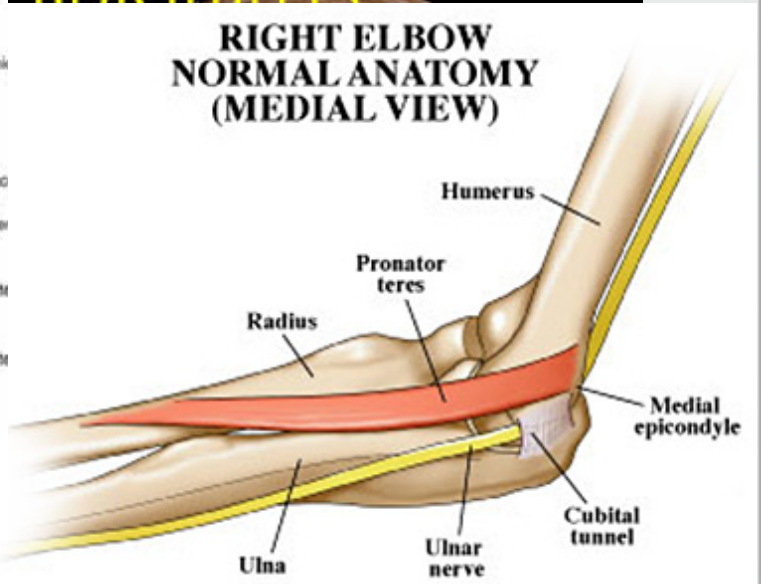

Brachial Plexus Injury

- Superior injuries (C5-C6)
  - Result from excessive increase in angle between neck and shoulder
- Inferior injuries (C7-T1)
  - Occurs when upper limb pulled suddenly superior